MR Arthrography of the Ankle: Indications and Technique

Luis Cerezal, MD[a,*], Eva Llopis, MD[b], Ana Canga, MD[c], Alejandro Rolón, MD[d]

KEYWORDS

• Ankle joint • Arthrography • Magnetic resonance imaging • Ankle injuries • Ligaments • Articular • Athletic injuries

MR imaging has become established as the most effective imaging technique in the diagnosis of articular pathology. MR arthrography is a minimally invasive procedure that extends the capabilities of conventional MR imaging. Intra-articular contrast permits capsular distention and delineates articular structures as it separates adjacent anatomic structures and fills potential spaces that communicate with the joint.

In recent years there has been rapid development and improvement of arthroscopic treatments in multiple joints such as the shoulder, hip, and wrist. As a result, musculoskeletal radiologists have been required to provide more accurate detection and characterization of articular pathology. MR arthrography has emerged as the imaging technique of choice for precise preoperative diagnosis in a spectrum of conditions, such as biceps pulley and biceps-labral complex injuries in the shoulder and femoroacetabular impingement syndrome in the hip. Despite the widespread use of MR arthrography for evaluation of intra-articular pathology at the shoulder, hip, and wrist, ankle MR arthrography is performed less frequently and its indications still seem to be limited. It should be recognized that MR arthrography can improve diagnostic accuracy in the context of certain ankle injuries and can greatly enhance the diagnostic utility of conventional MR imaging for a range of clinically suspected intra-articular pathologies. It is likely that future improvements in ankle arthroscopy will expand the indications for ankle MR arthrography.

Indirect MR arthrography with intravenous administration of gadolinium permits articular enhancement without capsular distention. For joints with less capacity for distention, such as the ankle, it is considered an alternative to direct MR arthrography in some cases.

This article reviews the role of ankle MR arthrography focusing on technique, pitfalls, complications, pertinent anatomy, and clinical applications.

DIRECT MR ARTHROGRAPHY TECHNIQUE

MR arthrography of the ankle is a two-step procedure involving intra-articular injection of contrast solution before MR imaging. The skin puncture can be performed in two main sites (**Fig. 1**A) at the anterior aspect of the ankle: immediately medial to the anterior tibial tendon or medial to the tendon of the extensor hallucis longus.[1–5] The arthrogram is usually performed under fluoroscopic control; however sonographic, CT, or MR guidance may be used.[6–11] Blind joint puncture can be performed in the MR imaging suite, using

[a] Radiology Department, Instituto Radiologico Cantabro, Clínica Mompía, Avenida de los Condes sn, Mompía 39108, Cantabria, Spain
[b] Radiology Department, Hospital de la Ribera, Carretera de Corbera km1, Alzira 46600, Valencia, Spain
[c] Radiology Department, Hospital Universitario Marqués de Valdecilla, Avenida de Valdecilla sn, Santander 39008, Cantabria, Spain
[d] Radiology Department, Centro de Diagnóstico Dr. Enrique Rossi, Arenales 2777 - CP: C1425BEE, Buenos Aires, Argentina
* Corresponding author.
E-mail address: lcerezal@gmail.com (L. Cerezal).

Radiol Clin N Am 46 (2008) 973–994
doi:10.1016/j.rcl.2008.09.002
0033-8389/08/$ – see front matter © 2008 Elsevier Inc. All rights reserved.

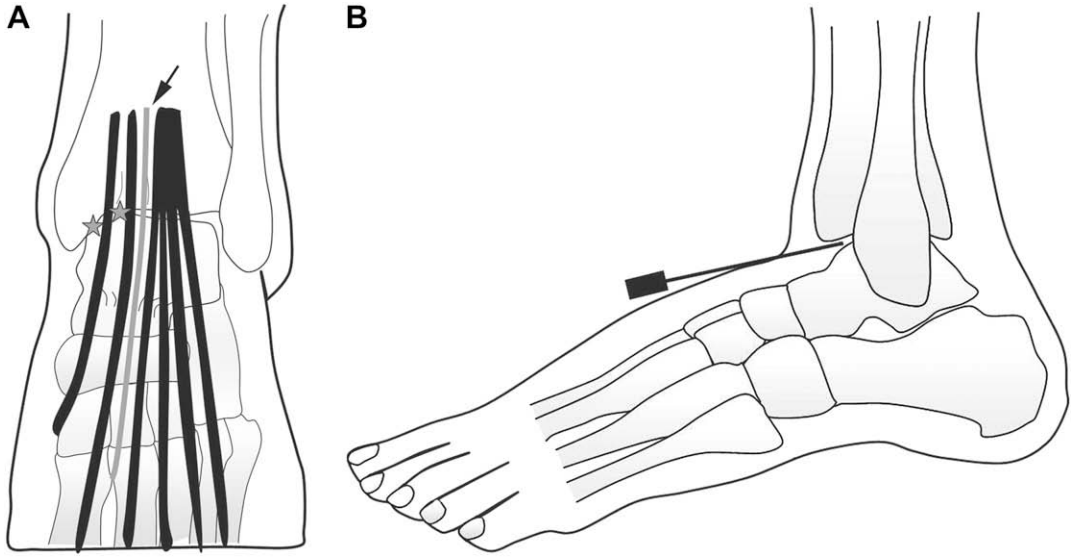

Fig. 1. Injection sites for ankle MR arthrography. (*A*) Anteroposterior view: Medial to anterior tibial tendon and medial to extensor hallucis longus tendon (*stars*). The course of dorsalis pedis artery (*arrow*) should be avoided, skin can be marked. (*B*) The needle is placed slightly cranial beneath the anterior lip of the tibia and advanced until its tip is seen between the distal tibia and the talus.

anatomic landmarks, thereby avoiding the need for iodinated contrast agents and ionizing radiation. Having achieved successful ankle arthrography under fluoroscopic guidance, blind ankle injection is easily performed.[1] The preferred puncture site is located at the level of the anteromedial ankle joint, just medial to the tibialis anterior tendon, approximately 5 mm proximal to the medial malleolus.

The authors recommend the following technique:[1,2] the patient is placed in lateral decubitus position with the ankle in the lateral position and the dorsal ankle facing the examiner. The course of the dorsalis pedis artery is palpated and marked to avoid arterial puncture. Using fluoroscopic guidance, a 22-23 gauge needle is inserted under sterile conditions into the tibiotalar joint medial to the anterior tibial tendon with a slight cranial tilt to avoid the overhanging anterior margin of the tibia (**Fig. 1**B). Before the injection of contrast material, any fluid within the joint is aspirated to avoid diluting the contrast material. Intra-articular needle placement is confirmed with an injection of 1 to 2 mL of iodinated contrast material. If the needle is intra-articular, the contrast medium flows away from the needle tip toward the capsular recesses. Subsequently, a mixture of 0.1 to 0.2 mL of gadolinium, 10 mL of saline solution, 5 mL of iodinated contrast material, and 5 mL of lidocaine 1% is injected until the joint capsule is properly distended (approximately 6–10 mL). The presence of iodinated contrast material in the mixture ensures correct needle position and adequate capsular distention.[12] To prevent capsular disruption, the contrast injection is stopped if the patient expresses discomfort or if high resistance is felt during the instillation of the solution. In the normal ankle, the injected contrast material forms an umbrella shape over the articular surface of the talus with prominence of the anterior and posterior capsular recesses. Cranial extension of contrast material is seen between the distal tibia and fibula into the syndesmotic recess. In up to 25% of cases the contrast solution enters the flexor hallucis longus and flexor digitorum longus tendon sheaths as well as the subtalar joint.[5] There should be no tendon sheath filling on the lateral side of a normal ankle. Following the injection, the needle is removed and the ankle is manipulated briefly to distribute the contrast medium uniformly.

Although saline solution may be used as MR arthrographic contrast material, saline is not an ideal contrast medium as it has the same signal characteristics as preexisting joint effusion and periarticular fluid.[6–11]

MR arthrography is a safe procedure without significant side effects. Studies have shown that patients who have undergone MR arthrography considered the discomfort less than expected.[13,14] The main complications of MR arthrography are joint pain, which may persist one to three days after joint puncture, and vasovagal reaction. Articular distention in arthrography produces a feeling of pressure in the joint and pain

of variable intensity on joint motion, which progressively decreases in the days following the procedure.[13] Vasovagal reactions may occur, particularly in young athletic patients with low resting heart rates; coexisting anxiety, apprehension, and pain increase the risk. Vasovagal reactions are easily managed in the radiology suite with prompt recovery. The routine administration of prophylactic atropine before ankle arthrography to block vasovagal reactions is unnecessary given the low incidence of these reactions (about 1% in the authors' experience). We believe that vasovagal reactions decrease when the patient is not allowed to see the needle or observe the procedure. Joint infection is an extremely rare major complication of arthrography that is independent of the type of substance injected into the joint.[13]

MR images is ideally performed within 20 to 30 minutes of injection, to minimize absorption of contrast and guarantee the desired capsular distention, although imaging delays of up to 1.5 to 2 hours are tolerated in the lower limbs joints.[5,15]

Imaging protocol sequences are oriented in axial, sagittal, and coronal planes with dedicated extremity coil and using small field of view to optimize the visualization of intra-articular structures. Several authors have used forced projections to stress ankle ligaments and improve its visualization, axial plane with dorsiflexion for anterior talofibular ligament (ATFL), or oblique coronal with plantar flexion for calcaneofibular ligament (CFL).[16] The choice of sequence depends on radiologist preference and MR device, but T1-weighted spin echo with and without fat saturation should be included. Three-dimensional gradient-echo images allow reconstruction in any plane making forced projections unnecessary and are also helpful detecting cartilage lesions and loose bodies. To rule out subtle bone marrow edema and extra-articular fluid collections, one sequence on T2-weighted fat suppression or short tau inversion recovery (STIR) is necessary.[1,2,4–11]

The most common pitfalls of MR arthrography of the ankle are extra-articular injection or reflux of contrast material through the capsular puncture site that can be confused with capsular disruption.[17] Accumulation of contrast material in the anterior and posterior recesses of the tibiotalar joint, which manifests as smooth, encapsulated fluid outside the ligaments, can be misinterpreted as a ligamentous tear. The bulbous appearance of the posterior talofibular ligament (PTFL) and posterior tibiofibular ligament (PITF) on sagittal images can simulate loose bodies. This pitfall is easily avoided by the evaluation of consecutive sagittal images and knowledge of the ligamentous anatomy. A pseudodefect of the talar dome is a normal groove at the posterior aspect of the talus. This defect should not be misinterpreted as an articular erosion or osteochondral defect.

Inadvertent use of undiluted gadolinium or higher gadolinium concentration dilution decreases signal-to-noise ratio and decreases signal intensity on T1-weighted imaging. This effect decreases with time; therefore, delay images could be helpful. The instillation of air bubbles during injection may mimic loose bodies; although air bubbles tend to rise to nondependent regions of the joint (**Fig. 2**), whereas loose bodies fall dependently.[1,5,11]

INDIRECT MR ARTHROGRAPHY

Indirect MR arthrography has been proposed as an alternative to direct MR arthrography. Intravenous administration of a standard dose of gadolinium followed by 5 to 10 minutes of light exercise can provide arthrogram-like images of the ankle joint.[18–22] Imaging delay is essential, as time is required for the contrast agent to transfer from the blood pool into the joint. The degree of articular enhancement is dependent on the blood concentration of contrast, joint volume, intra-articular pressure, synovial area, inflammation and permeability, and the time delay following contrast injection. These variables are difficult to control and result in the heterogeneous quality of indirect MR arthrography.[19]

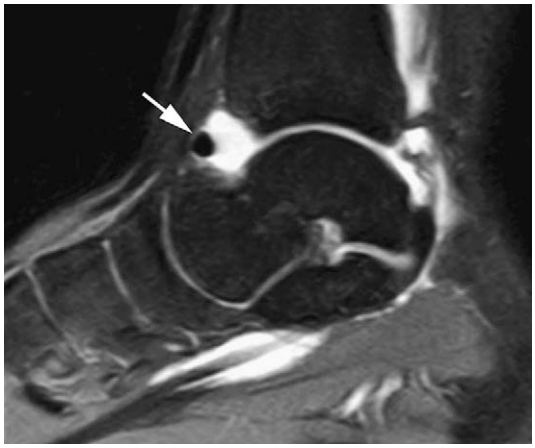

Fig. 2. Inadvertent injection of air in MR arthrography mimicking a loose body. Sagittal fat suppressed T1-weighted MR arthrogram image of the right ankle shows a gas bubble located in the upper part of the joint (*arrow*). Most air bubbles can be easily distinguished from loose bodies by their nondependent position and typical appearance caused by susceptibility artifact.

The main drawback of indirect MR arthrography is the lack of capsular distention. Another limitation is that juxta-articular structures, such as vessels, and the synovial membranes of bursae and tendon sheaths also demonstrate enhancement, which can lead to confusion with capsular disruption or the presence of abnormal joint recesses.

Indirect MR arthrography may be useful in detection of subtle cartilaginous defects with enhancement of the cartilaginous defect and the subchondral bone due to trabecular disruption and hyperemia.[18–22]

In the assessment of osteochondral lesions of the talus with indirect MR arthrography, high signal intensity on T1-weighted imaging surrounding the bone fragment interface is a sign of a loose osteochondral fragment, which might be secondary to synovial fluid entering the defect indicating partial or complete detachment of the fragment or granulation tissue enhancement, correlation with signal intensity on T2-weighted sequence helps to differentiate detachment fragment which has higher T2-weighted signal intensity following fluid signal than granulation that is slightly lower signal intensity on T2-weighted (**Fig. 3**).[18–22]

Partial ligament tears may be identified by focal enhancement indicating hyperemia. Complete tears may be seen as enhanced joint fluid extending into the ligament defect.

Indirect MR arthrography may also be useful in the evaluation of anterolateral impingement outlining the impinging lesion in the anterolateral gutter of the ankle.[18–22]

Indirect MR arthrography provides further assessment of extra-articular soft tissues of the ankle. Enhancement of extra-articular structures can highlight focal pathology while lack of abnormal enhancement invariably indicates absence of disease in the region of interest. For instance, enhancement around the plantar fascia is observed in patients with plantar fasciitis. Enhancement of fluid within the tendon sheath indicates tenosynovitis. Synovitis in the region of the tarsal tunnel with enhancement around the posterior tibial nerve may suggest tarsal tunnel syndrome. Focal enhancement in the region of the sinus tarsi suggests sinus tarsi pathology.[18–22]

INDICATIONS

Indications for the use of MR arthroscopy include: ligamentous injuries, ankle impingement syndromes, osteochondral and cartilage lesions, intra-articular loose bodies, and adhesive capsulitis. The anatomy, pathophysiology, imaging, and treatment of each is discussed below.

Ligamentous Injuries

The ankle joint is stabilized by three ligamentous groups: the distal tibiofibular ligamentous or syndesmotic complex, the lateral collateral ligament (LCL) complex, and the deltoid ligament.[22–24]

Ankle sprains are common and account for up to 10% of emergency department visits and are the most common sports-related injury, accounting for 16% to 21% of all sports-related injuries.[25,26] Athletic activities requiring frequent pivoting and jumping are particularly susceptible to ankle injuries, so the highest incidences of ankle sprains are found in sports such as football, soccer, and basketball.[25]

Approximately 85% of all ankle sprains are due to inversion forces involving the LCL complex.[22–25] Syndesmotic sprains are the second most prevalent (10%), followed by isolated medial sprains. Multiligamentous injuries are frequent: an inversion

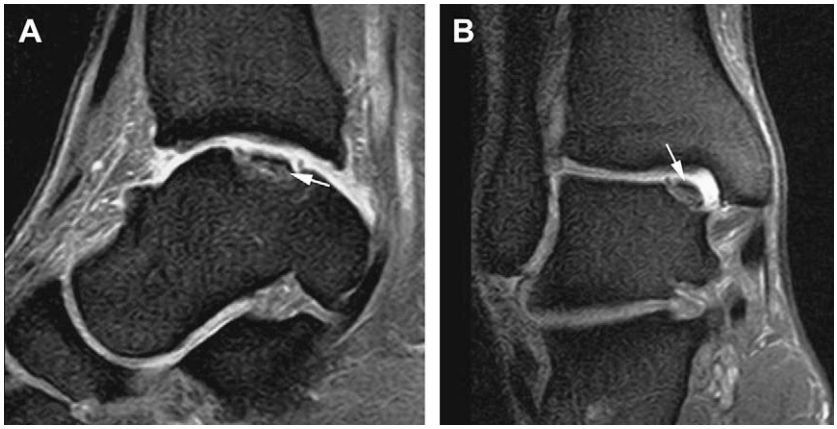

Fig. 3. Stage III osteochondral lesion of the talus. (*A, B*) Sagittal and coronal fat-suppressed T1-weighted indirect MR ankle arthrogram of the right ankle show contrast-enhanced fluid around osteochondral lesion of the talar dome (*arrows*) which indicates complete loosening of the osteochondral fragment.

mechanism often involves both lateral and syndesmotic ligaments, whereas an eversion mechanism may affect both deltoid and syndesmotic ligaments.

Regardless of the pattern of injury, the outcome of ankle sprain is similar. As such, clinical evaluation with or without conventional radiography is sufficient. However, chronic pain or instability can limit activity and affect up to 20% to 40% of patients following ankle sprain.[27]

MR arthrography improves visualization of the ankle ligaments. The role of MR arthrography is in preoperative planning for chronic ankle pain, to determine the extent and severity of ligamentous injuries, and to identify associated intra-articular pathology; especially to determine causes of ankle impingement syndromes.

Lateral collateral ligament complex

Anatomy The LCL complex includes three ligaments: ATFL, CFL, and PTFL.[23,24,26] The ATFL is located within the anterolateral joint capsule extending from the anteroinferior aspect of the lateral malleolus to the lateral talar neck. The CFL is a cord-like structure that arises from the tip of the lateral malleolus and passes obliquely downward and posterior to insert at the posterolateral aspect of the calcaneus. It is an extra-articular structure and forms the floor of the peroneal tendon sheath. The CFL controls two joints, talocrural and subtalar; unlike the other two elements of LCL, which only support the talocrural joint. The PTFL is an intra-articular ligament that arises from the medial aspect of the distal fibula and passes almost horizontally to insert along the posterolateral tubercle of the talus. On MR imaging the ATFL is better visualized in the axial plane, CFL in the axial or coronal plane, and PTFL in the axial or coronal plane.

Pathophysiology Plantar flexion with inversion and internal rotation of the foot is the most common mechanism of ankle injury and follows a predictable sequence: ATFL is torn first, followed by CFL and, only under extreme inversion, the PTFL is torn usually with an avulsion fracture. Isolated tear of CFL is unusual.[24–26]

Chronic pain secondary to lateral ankle sprains presents a diagnostic and therapeutic challenge, as it can be due to a variety of pathology, including: instability, soft-tissue impingement, post-traumatic arthritis, syndesmotic injuries, sinus tarsi syndrome, subtalar instability, peroneal tendon lesions, or osteochondral lesions of the talar dome.[27–29]

Patients describe ankle instability as recurrent, intermittent episodes of a feeling of "giving way" with asymptomatic periods in between.[30–32] It can be divided into mechanical or functional. Instability without evidence of anatomic ligamentous injury is referred as "functional instability" whereas when specific ligament incompetency (mobility beyond the physiologic range of motion) is termed "mechanical instability." The reported prevalence of functional instability ranges from 15 to 60% following ankle sprain, and appears to be independent of the severity of the initial injury. Mechanical instability is less prevalent.[29–32]

Imaging

MR imaging Indications for MR imaging to evaluate ligamentous injury and instability are limited to: the evaluation of acute ankle injuries with instability, stable acute injuries suffered by athletes or in cases of litigation, and patients with repeated injuries or chronic ankle instability in whom surgery is contemplated. MR imaging may depict lesions commonly associated with ligament injuries, such as impingement syndromes, sinus tarsi syndrome, osteochondral lesions, and tendon tears.[23,24]

Ankle ligaments are readily identified on MR images as low-signal intensity structures joining adjacent bones usually delimited by contiguous high signal intensity fat. Heterogeneity and striation may be noted in some ligaments, such as the PTFL or deep component of the deltoid ligament, owing to the presence of interposed fat between their fascicles.[33]

MR imaging criteria for the diagnosis of acute tears of the ankle ligaments include morphologic and signal intensity alterations within the ligament (primary signs) or surrounding the ligament (secondary signs). Primary signs of ligament tear include: discontinuity, detachment, nonvisualization, or thickening of the ligament associated with increased intrasubstance signal intensity on T2-weighted images indicative of edema or hemorrhage. Secondary signs of acute ligament injury include: extravasation of joint fluid into the adjacent soft tissues, joint effusion, and bone bruises. Fluid within the peroneal tendon sheath is an important secondary sign of acute CFL injury. In chronic tears secondary signs disappear and the ligament can appear thickened, thinned, elongated, with an irregular or wavy contour.[23,24,33] Avulsion injuries are easily diagnosed in either the acute and chronic setting as a bone fragment adjacent to an irregular lateral or medial malleolus.

MR arthrography Normal ankle ligaments of the LCL complex are better depicted by MR arthrography as compared with conventional MR imaging.[1–5,16] Intra-articular joint distention with diluted contrast lifts the ligaments away from the

adjacent bones, outlining the ligaments and improving their visualization. MR arthrography allows precise assessment of the thickness of the ligaments and their integrity at insertion sites.

Nonvisualization of the ligament or extravasation of contrast material anterior to the ATFL indicates tear of the ligament (**Figs. 4** and **5**). A capacious anterior recess of the ankle joint which may permit the contrast agent to outline the anterior border of the capsular ligament due to capsular distention beyond the ligament should not be confused with a tear. Disruption of the CFL often results in pathologic communication of contrast material lateral to the ligament from the ankle joint into the peroneal tendon sheath (see **Fig. 5**), which is attached to the superficial surface of the ligament. Therefore, contrast material in the peroneal tendons sheath at MR arthrography is an indirect but specific sign of CFL injury. Extravasation of contrast material into the soft tissues posterior to the PTFL indicates a tear of this ligament.[1–5,16]

Treatment Treatment of injuries to lateral ankle ligaments is conservative. Surgical management of ankle sprains is rarely indicated, and is limited to ankle instability refractory to conservative treatment. Numerous surgical techniques have been described to correct ankle instability with an 80% to 90% success rate.[31,34] Current methods of direct repair of the ATFL and CFL offers better functional results than reconstructive techniques using tendon transfer.[29–32,34]

Syndesmosis

Syndesmotic ligament injuries, also known as high ankle sprains, are the second most prevalent ankle ligament injury (10%).[23,24,27,35] The incidence of syndesmotic sprains is probably higher than reported,[23,24,35,36] and occurs as an isolated injury or in association with lateral and medial collateral ligament injuries. Syndesmotic disruption is commonly associated with Lauge-Hansen fractures (Weber B and C). The injury is common in young athletic individuals, especially those involved in contact sports, such as soccer and football.[26]

Syndesmotic injuries are more debilitating than lateral collateral ligament sprains and require a longer recovery time. Isolated syndesmotic injuries often do not present with appreciable diastasis and can be difficult to diagnose, leading to underestimation of injury, incomplete rehabilitation, and prolonged pain and disability.[27,35]

Anatomy Three ligaments join the distal tibial and fibular epiphyses: the anterior or anteroinferior tibiofibular ligament (AITF), the PITF, and the interosseous tibiofibular ligament.[37] The AITF has a multifascicular morphology and is the weakest of the three. The most distal fascicle of the AITF seems to be an independent structure, situated slightly deeper and separated by a fibroadipose septum from the rest of the ligament. The AITF normally contacts the dorsolateral border of the talus during ankle dorsiflexion and eversion.[37] Nikolopoulous[38] considered the accessory AITF to be a separate structure from the AITF with

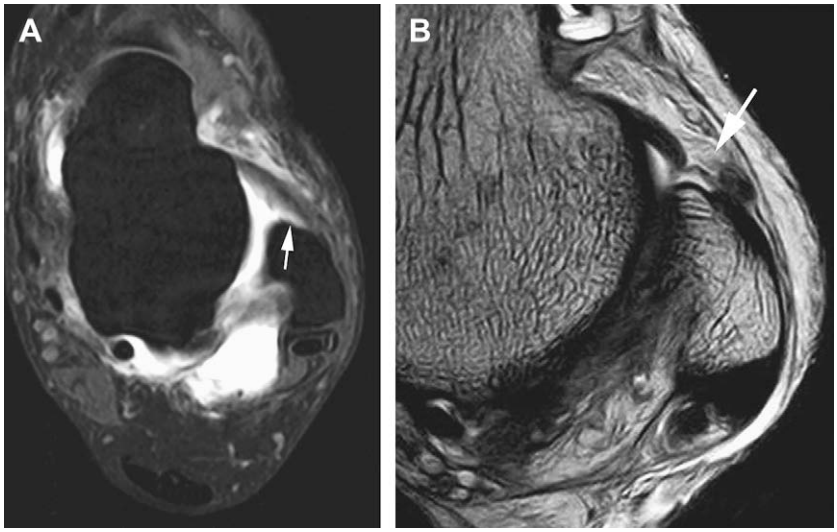

Fig. 4. Chronic tear of the ATFL. (*A*) Axial fat-suppressed T1-weighted MR arthrogram image shows diffuse irregular thickening and partial detachment at peroneal insertion of the ATFL (*arrow*). (*B*) Axial T1-weighted MR arthrogram image demonstrates focal disruption of the peroneal insertion of the ATFL (*arrow*).

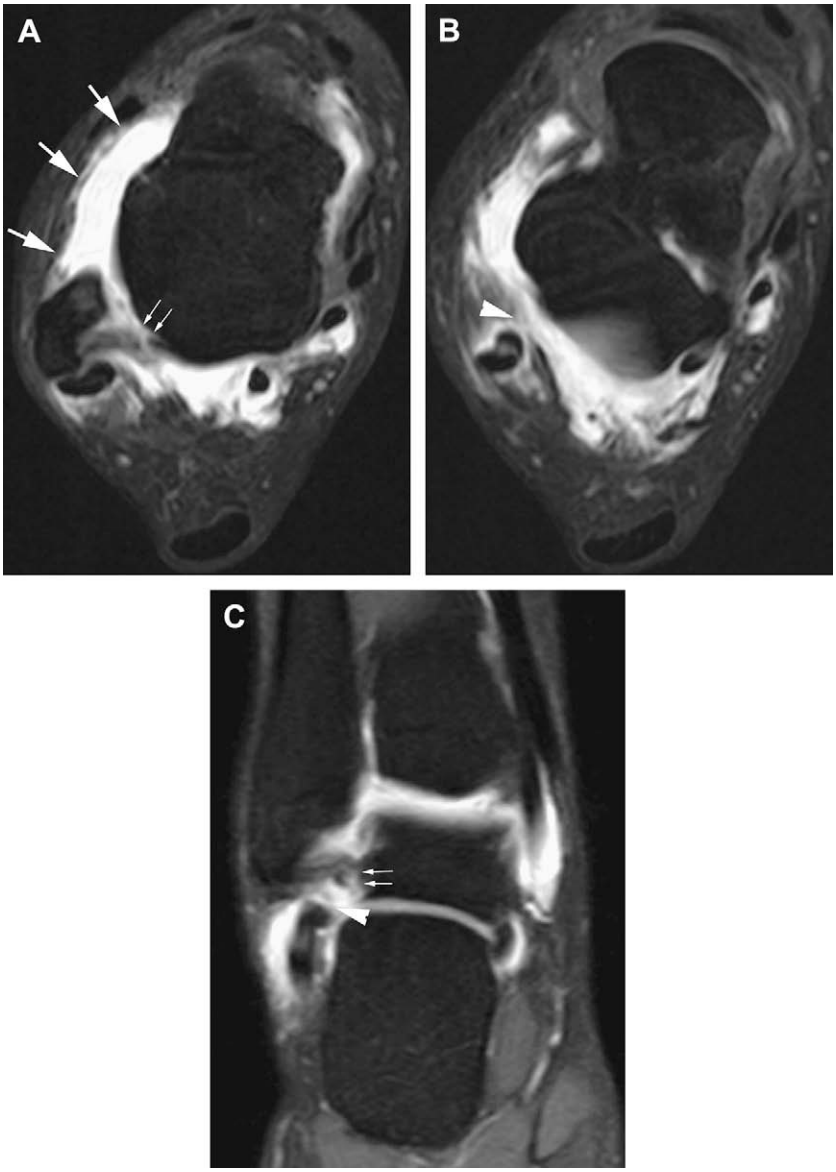

Fig. 5. Chronic complete tear of the ATFL and CFL, and partial disruption of the PTFL. (*A–C*) Axial and coronal fat suppressed T1-weighted MR arthrogram images of the right ankle show complete absence of the ATFL (*arrows in A*), complete rupture of the CFL with contrast communication with the peroneal tendon sheath (*arrowheads in B and C*), and partial disruption of the PTFL at the insertion on posterolateral tubercle of the talus (*small arrows in A and C*).

a reported incidence of 21% to 92%.[38] This theory was refuted by Bassett and colleagues,[39] whose anatomic cadaveric study designated the distal fascicle of the AITF as a constant structure (also known as Bassett's ligament).

The PITF is formed by two components: one superficial and one deep or transverse ligament. The interosseous tibiofibular ligament is simply the continuation of the interosseous membrane at this level.[24,37]

There is a synovial-lined interosseous recess or diverticulum that extends from the ankle joint, between the distal tibia and fibula, and ends close to the base of the interosseous ligament. The recess is formed by a posteriorly located V-shaped synovial plica that blends laterally with the fibula.[37] The medial aspect of the plica lies loosely on the tibia, creating the diverticulum. The normal tibiofibular recess measures approximately 1 cm in height in anatomic studies and averages 0.5 cm on MR imaging.[36]

Pathophysiology Syndesmotic ligaments stabilize the distal tibiofibular articulation and prevent diastasis of the tibia and fibula at the ankle. The most common mechanism of injury is pronation and eversion of the foot combined with internal rotation of the tibia on a fixed foot. Syndesmotic injuries are frequently associated with eversion-type ankle fractures, particularly high fibular fractures (Weber B and C), and rupture of the deltoid ligament.[27–29] Syndesmotic sprains requires a longer recovery period than isolated LCL sprains. Incomplete reduction of syndesmotic injury may produce chronic syndesmotic widening, persistent pain, and ankle arthrosis.

Imaging

MR imaging MR imaging is sensitive and specific for identification of tibiofibular syndesmotic injuries. Findings indicative of a syndesmotic interruption include ligament discontinuity, contour alteration (wavy or curved ligaments), or ligament nonvisualization.[36,40] Using these criteria, the reported sensitivity and specificity of MR imaging compared with arthroscopy are 100% and 83% to 92%, respectively.[40] Common findings associated with syndesmotic injury include an increase in the height of the tibiofibular recess, osteochondral lesions of the talus (28%), and tibiofibular joint incongruity (33%).

MR arthrography MR arthrography permits better assessment of syndesmotic injury, which appears as thickening, nonvisualization, or irregularity of the syndesmotic ligaments (**Fig. 6**), and is helpful for detection of associated lesions.[1,16] The oblique course of the syndesmotic ligaments must be kept in mind when assessing syndesmotic tears, because they may appear falsely torn on routine axial images. In addition, the normal fascicular pattern, especially of the AITFL, should not be misinterpreted as a tear.[1]

A common indirect finding in syndesmotic ligament complex injury on MR arthrography is an increase in the height of the tibiofibular recess, averaging 1.2 cm in acute tears and 1.4 cm in chronic tears.

Treatment Treatment of isolated syndesmotic ligament injury without diastasis is conservative. Indications for surgery are: symptoms refractory to conservative management, presence of diastasis on routine or stress radiographs, and delayed presentation of more than three months. A complete tear is managed by suture of the ligament and temporary fixation of the tibia and fibula with a syndesmosis screw, cerclage or Kirschner wires.[29–34]

Deltoid ligament

Deltoid ligament sprains without other ligamentous injuries are rare (5% of all ankle ligament injuries).[23,24,27,41] Deltoid or medial collateral ligament (MCL) sprain is often more painful than lateral ankle sprain and can be a significant source of chronic medial ankle pain.[42] Sequelae of deltoid ligament tear include: ankle instability, chondral injuries, ankle joint arthritis, and medial impingement.[41]

Anatomy Deltoid ligament anatomy is confusing since the division of its components is difficult

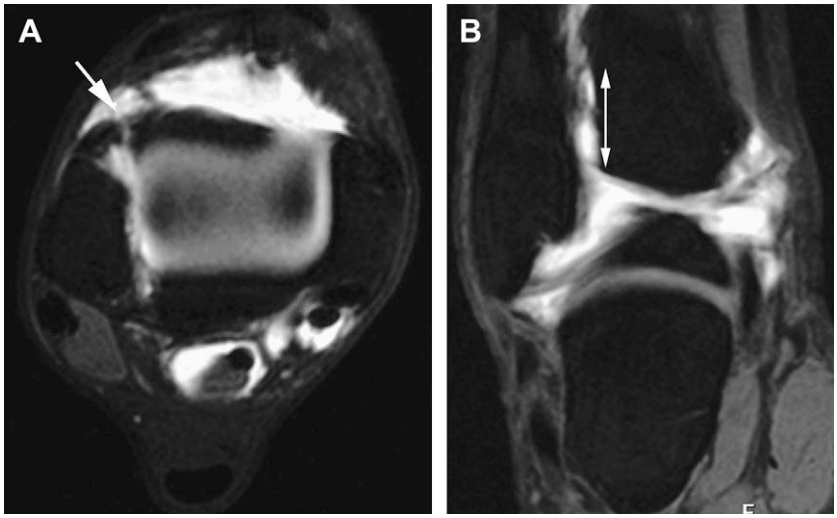

Fig. 6. Chronic syndesmosis sprain. (*A, B*) Axial and coronal fat suppressed T1-weighted images of right ankle show thickening and complete disruption of the AITF (*arrow*), and increase in the height of the tibiofibular recess (*double-headed arrow*).

during dissection, and its origins and insertions are complex.[37] Most investigators agree that the MCL has a superficial and deep layer.[37,43] Milner and Soames[43] describe the deltoid ligament as being composed of four superficial (tibionavicular, tibiospring, tibiocalcaneal, and superficial posterior tibiotalar) and two deep (anterior and posterior tibiotalar) bands or components.[24,37] The deltoid ligament blends with the tendon sheaths of the posterior tibial tendon, flexor hallucis longus, and flexor digitorum longus tendons. The superficial layer of the ligament crosses both the ankle and subtalar joints, whereas the deep layer only crosses the ankle joint.[43]

Pathophysiology Traumatic deltoid ligament injury is most commonly associated with concomitant malleolar fracture, lateral ankle sprain, and syndesmotic injury; whereas nontraumatic injuries occur frequently in patients with posterior tibial tendon dysfunction.[23,24,41,43] Isolated ruptures of the deltoid ligament are rare but can occur as a consequence of an eversion-lateral rotation mechanism. Contusions and partial tears of the deltoid ligament, particularly of its posterior tibiotalar component, are frequently associated with inversion sprains, in which the deep posterior fibers of the medial deltoid ligament are crushed between the medial wall of the talus and the medial malleolus.[42]

Imaging

MR imaging The normal uninjured bands of the MCL can usually be easily distinguished from one other, optimally seen in the coronal and axial plane.[23,24,33] Deltoid ligament injury is clearly demonstrated by MRI as morphologic and signal alterations of the ligament. Loss of the normal striated appearance and increased interstitial signal of the deep tibiotalar component are common findings. Interstitial edema signal is not infrequently seen on MR imaging in stable ankles and likely reflects contusion rather than a tear of the tibiotalar component of the deltoid ligament. Thickening or attenuation of the deltoid ligament may be seen with healing.[23,24,33] Osseous abnormalities that are associated with deltoid ligament injury include fibular and medial malleolar fractures, bone bruises at the medial malleolar/tibial plafond junction, and talar displacement. Concomitant LCL and syndesmotic ligament injuries are also common.

MR arthrography MR arthrography with optimal articular distention outlines the deep deltoid ligament and improves evaluation of partial tears (**Fig. 7**).[1] Detection of associated lesions, such as chondral and osteochondral defects, and medial impingement is also improved with MR arthrography.[1]

Treatment Management of deltoid ligament injury focuses on associated bone or ligamentous injuries. Partial deltoid ligament tears are managed conservatively. Isolated complete acute deltoid tear, avulsion of the medial malleolus, and chronic deltoid sprains are surgically repaired using arthroscopy or open reduction.[41]

Ankle Impingement Syndromes

Ankle impingement syndromes are chronic, painful conditions due to repetitive friction of joint tissues, precipitated and exacerbated by altered ankle joint biomechanics.[44,45] The main cause of impingement lesions is posttraumatic ankle injury, usually ankle sprain. Ankle impingement syndrome is a clinical exclusion diagnosis; its symptoms

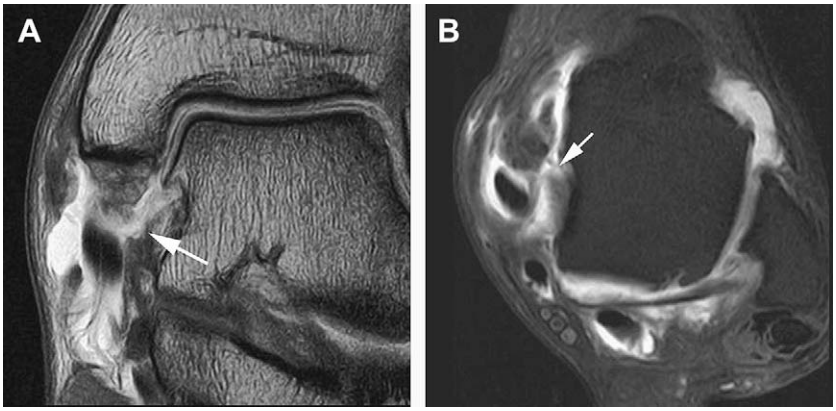

Fig. 7. Chronic complete tear of the deltoid ligament. (*A*) Coronal T1-weighted and (*B*) axial fat suppressed T1-weighted MR arthrogram images of left ankle demonstrate complete tear of the deltoid ligament involving both superficial and deep components (*arrows*).

mimic a wide variety of common disorders such as osteochondral fracture, mechanical instability, peroneal tendon rupture, subluxation or tenosynovitis, and sinus tarsi syndrome.

These syndromes are classified in anatomic and clinical terms as anterolateral, anterior, anteromedial, posteromedial, and posterior.[44,46–48]

Careful analysis of patient history, and signs and symptoms at physical examination can suggest a specific diagnosis in most patients. MR imaging and MR arthrography are the most useful imaging methods for detecting the osseous and soft-tissue abnormalities present in these syndromes and for ruling out other potential causes of chronic ankle pain.[44,46]

The initial treatment of all ankle impingement syndromes is conservative, but when this fails, arthroscopic examination is indicated to identify and resect the impinging lesion.[1,2]

Anterolateral impingement syndrome

Prevalence, epidemiology, and definitions Anterolateral impingement is a relatively uncommon cause of chronic ankle pain produced by entrapment of abnormal soft tissue in the anterolateral gutter of the ankle after single or multiple ankle inversion injuries (**Fig. 8**). The anterolateral recess of the ankle is defined by the talus and tibia posteromedially, the fibula laterally, and the anterior ankle joint capsule along with the AITF, ATFL, and CFL anteriorly. The space extends inferiorly to the CFL and superiorly to the tibial plafond and distal tibiofibular syndesmosis.[49,50] Approximately 3% of ankle sprains may lead to anterolateral impingement. This type of ankle impingement is most common in athletic young males.[49,50]

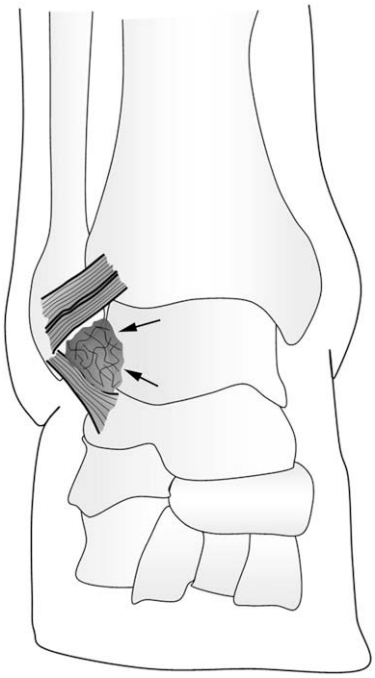

Fig. 8. Anterolateral impingement syndrome: typical location of anterolateral ankle impingement, with irregular fibrosis and synovitis in the anterolateral capsular recess of tibiotalar joint (*arrows*).

Pathophysiology Anterolateral impingement is thought to occur subsequent to relatively minor trauma involving forced ankle plantarflexion and supination. Repeated microtrauma produce synovial scarring, inflammation, and hypertrophy in the anterolateral gutter of the ankle, and may cause impingement. Wolin and colleagues[51] coined the term "meniscoid lesion" owing to its resemblance at surgery to meniscal tissue.

Other contributing factors are osseous spurs and hypertrophy of the inferior fascicle of the AITF.[44,46] A chronic ATFL tear results in anterolateral joint laxity, permitting anterior talar extrusion in dorsiflexion and increasing contact between the talus and the inferior fascicle of the AITF or Bassett ligament. Constant rubbing of the fascicle against the talus thickens the fascicle, developing an impinging lesion in the anterolateral gutter. This condition has also been referred to as "syndesmotic impingement." There may be associated chondral abrasion at the apposed anterosuperior lateral margin of the talus.[37,44,46]

Imaging

MR imaging There is controversy about the accuracy of the MR imaging for the diagnosis of anterolateral impingement, but most of the authors believe that assessment of the anterolateral recess with conventional MR imaging is only accurate when a substantial joint effusion is present.[48]

MR arthrography MR arthrography has proved to be an accurate technique for assessing the presence of soft tissue scarring in the anterolateral recess of the ankle and determining its extent in patients with anterolateral impingement before arthroscopy, seen as a nodular or irregular deep contour of the anterolateral joint capsule (**Fig. 9**).[1,52] Robinson and colleagues[52] found that MR arthrography was 100% accurate for evaluation of soft tissue abnormality in 13 patients with suspected clinical anterolateral impingement that had scarring and synovitis in the anterolateral recess. A highly specific but insensitive MR arthrographic finding is the absence of a normal fluid-filled recess between the anterolateral soft tissues and the anterior surface of the fibula. This may be due to the presence of adhesions and scar tissue that impairs the entrance of fluid into the normal recess between the fibula and joint capsule.

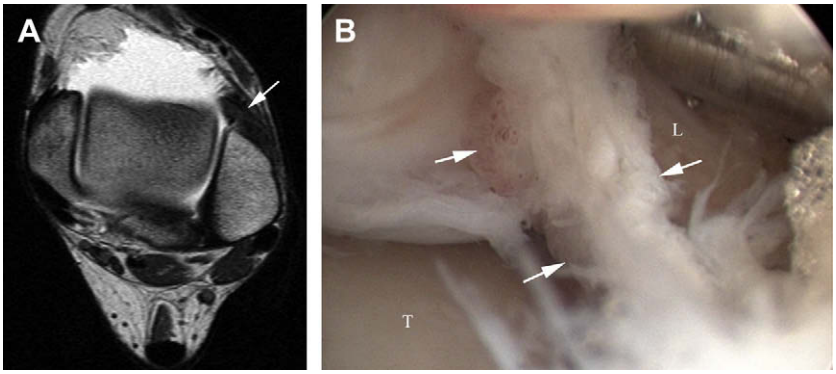

Fig. 9. Anterolateral impingement syndrome. (*A*) Axial T1-weighted spin echo MR arthrography of left ankle shows irregular soft tissue thickening in the anterolateral gutter (*arrows*). (*B*) Arthroscopic image demonstrating scarring and synovitis in the anterolateral gutter (*arrows*). L, lateral malleolus; T, talus.

Clinical correlation is essential because abnormal soft tissue scarring with or without synovitis can be seen in asymptomatic patients.[46,52]

Articular distention by MR arthrography allows more precise diagnosis of anterolateral impingement caused by thickening of the inferior fascicle of the AITF ligament (syndesmotic impingement) (**Fig. 10**). Fibrosis and focal synovitis often are observed surrounding the AITF ligament in syndesmotic impingement.[1,45]

Anterior impingement syndrome

Prevalence, epidemiology, and definitions Anterior impingement is a relatively common cause of chronic anterior ankle pain, especially in young athletes subjected to repeated stress in dorsiflexion of the ankle, such as soccer players and dancers.[44,46,47,53]

Pathophysiology The origin of anterior impingement is uncertain, and many mechanical factors are probably involved.[46,53] Three different hypotheses have been proposed to explain the formation of talotibial osteophytes in the anterior ankle impingement syndrome.[53] Forced dorsiflexion results in repeated microtrauma on the tibia and talus, leading to microfractures of trabecular bone or periosteal hemorrhage, healing with new bone formation. Another mechanism suggested is forced plantarflexion trauma, with capsular avulsion injury. However, the majority of the talotibial osteophytes are not located at the capsular attachment but are found in arthroscopy to be intra-articular at the anterior tibiotalar articular margin, approximately 5 to 8 mm distant from the capsular attachments.[53] Thus this hyperplantarflexion mechanism has been largely discredited. A recent hypothesis has suggested that formation of osteophytes in the ankle is related to direct damage to the rim of the anterior ankle cartilage combined with recurrent microtrauma, such as by direct impact of a soccer ball on the anterior ankle region.

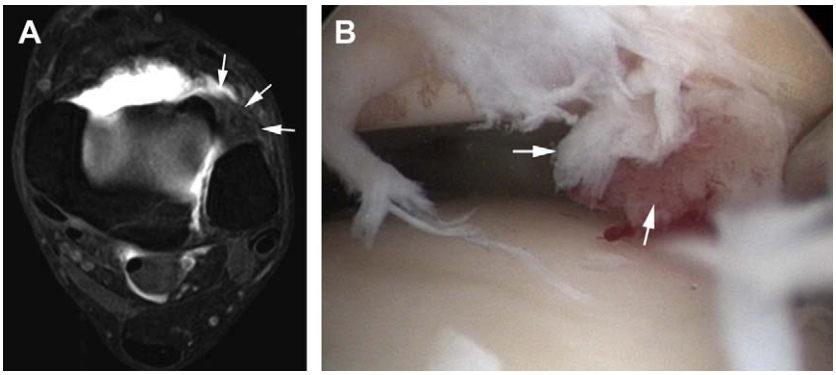

Fig. 10. Anterolateral impingement syndrome. (*A*) Axial fat-suppressed T1-weighted spin echo MR arthrogram of left ankle demonstrates nodular irregular lesion surrounding inferior fascicle of AITF (Bassett's ligament) in the superior aspect of the anterolateral gutter (*arrows*). (*B*) Corresponding arthroscopic image showing focal fibrosis and synovitis (*arrows*) surrounding inferior fascicle of AITF.

Once formed, forced dorsiflexion of the ankle causes impingement between reciprocating talotibial "kissing" lesions (**Fig. 11**).[44–47,53]

Imaging Conventional radiography is the only imaging study required in most cases, allowing evaluation of osseous spurs and the tibiotalar joint space. An oblique ankle radiograph, anteromedial impingement view, is a useful adjunct to routine views to detect tibial and anteromedial talar osteophytes.[53]

MR imaging MR imaging is useful to confirm the diagnosis, to depict associated findings and to rule out other causes of chronic ankle pain. The presence of anterior tibiotalar joint effusion and bone marrow edema in the anterior talar neck or distal anterior tibia are the findings most consistent with symptomatic anterior impingement.[44]

MR arthrography MR arthrography is useful in assessing the degree of cartilage damage, in delineating loose bodies, and in the detection of capsular thickening and synovitis in the anterior capsular recess (**Fig. 12**).[44,46]

Medial impingement syndrome

Prevalence, epidemiology, and definitions Medial impingement is an uncommon cause of chronic ankle pain after an ankle trauma. Medial impingement is commonly associated with lateral and medial ligament injury. Depending on its anatomic location it is referred to as anteromedial or posteromedial impingement.[44,46,54,55]

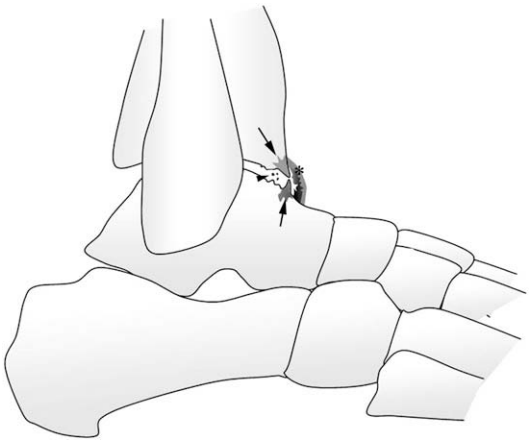

Fig. 11. Anterior impingement syndrome. Diagram shows typical features of anterior ankle impingement including chondral fraying, anterior tibial and talar osteophytes (*arrows*), synovitis in anterior capsular recess (*asterisk*), reduction of joint space, and osteochondral loose bodies (*arrowhead*).

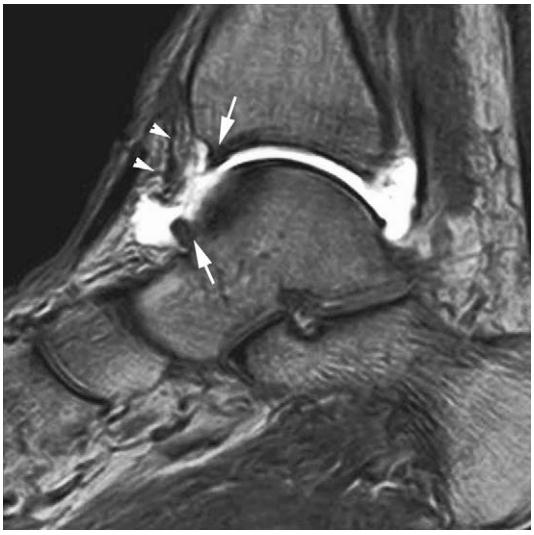

Fig. 12. Anterior impingement syndrome. Sagittal T1-weighted spin echo MR arthrogram of right ankle shows anterior tibial and talar osteophytes ("kissing lesion") (*arrows*), and irregular soft tissue mass in the anterior capsular recess (*arrowheads*).

Pathophysiology Medial impingement is rarely an isolated condition; it is most commonly associated with an inversion mechanism resulting in lateral ligament injury. It can occur after a severe ankle-inversion injury with the deep anterior or posterior fibers of the deltoid ligament becoming crushed between the talus and the medial malleolus. Inadequate healing of the contused deep deltoid ligament fibers may lead to chronic inflammation and fibrosis. In these cases, the anomalous soft tissue may impinge between the medial wall of the talus and the medial malleolus (**Fig. 13**).[44,46,54,55]

Imaging Conventional MR imaging has not been proved useful for diagnosis of anteromedial ankle impingement.

MR arthrography MR arthrography is the imaging method of choice, clearly defining a medial meniscoid lesion (**Fig. 14**), thickened and irregular tibiotalar ligaments, capsular abnormalities, and chondral or osteochondral associated lesions.[44–46,55] Occasionally, MR arthrography reveals the existence of fibrosis encasing the sheaths of the internal retromalleolar tendons that can interfere with the proper sliding of the medial posterior tendons and contribute to medial ankle pain in patients with medial impingement (see **Fig. 14**).

Posterior impingement syndrome

Prevalence, epidemiology, and definitions Posterior ankle impingement syndrome is a clinical disorder characterized by posterior ankle pain, including

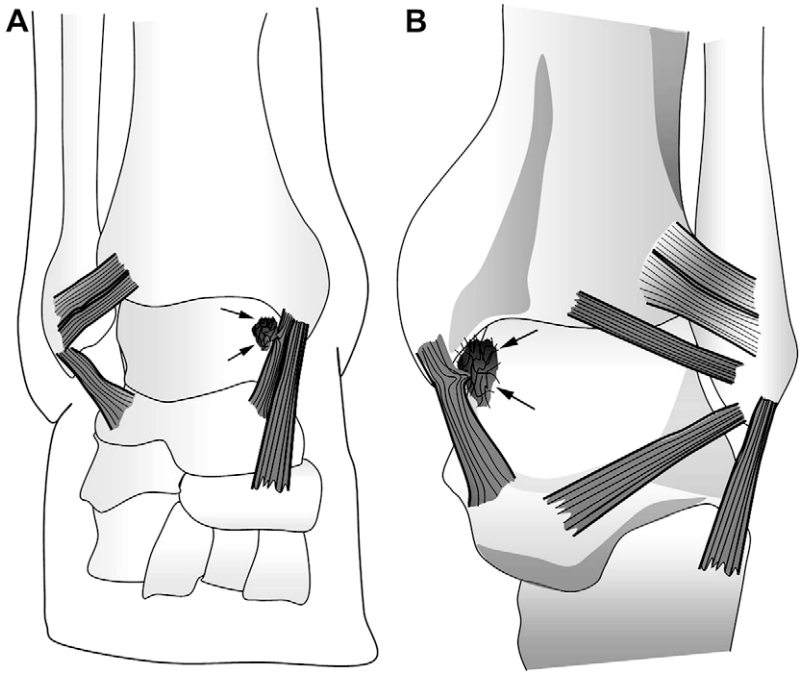

Fig. 13. Anteromedial and posteromedial ankle impingement. Diagrams illustrating findings of anteromedial (*A*) and posteromedial (*B*) ankle impingement including meniscoid lesions (*arrows*), and thickened anterior or posterior tibiotalar ligaments.

a group of pathologic conditions secondary to repetitive or acute forced plantarflexion of the foot, which produce compression of the talus and surrounding soft tissue between the tibia and the calcaneus.[44,46,56]

Pathophysiology Posterior impingement has been described as a "nut in a nutcracker" mechanism. The posterior talus and surrounding soft tissues are compressed between the tibia and the calcaneus during plantarflexion of the foot.[44,46,56]

Posterior ankle impingement syndrome may manifest as an inflammation of the posterior ankle soft tissues, as an osseous injury, or as a combination of both. The most common

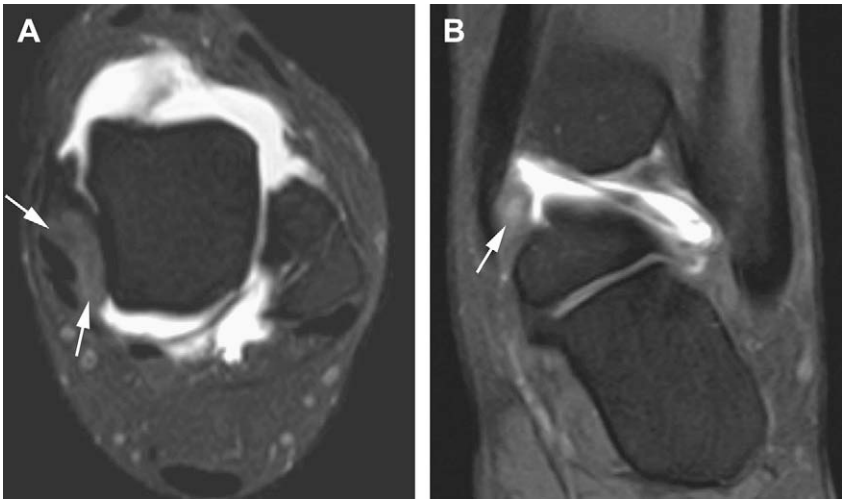

Fig. 14. Posteromedial impingement syndrome. (*A, B*) Axial and coronal fat-suppressed T1-weighted MR arthrograms of the left ankle show hypertrophic fibrotic tissue in the posteromedial aspect of the ankle (*arrows*) behind the posterior tibiotalar ligament and deep to the posterior tibial tendon.

causes are osseous (**Fig. 15**), such as the os trigonum, an elongated lateral tubercle termed a "Stieda process," a downward sloping posterior lip of the tibia, the prominent posterior process of the calcaneus, and loose bodies. Injuries include fracture, fragmentation, and pseudarthrosis of the os trigonum or lateral talar tubercle.[44,46]

Soft tissue causes of impingement include synovitis of the flexor hallucis longus tendon sheath, the posterior synovial recess of the subtalar and tibiotalar joints, ganglia, low-lying flexor hallucis longus muscle belly, anomalous muscles, and the intermalleolar ligament (IML).[44,46,56]

The IML is a normal variant of the posterior ankle ligaments of the ankle that courses obliquely from lateral to medial and from downward to upward, connecting the malleolar fossa of the fibula to the medial posterior tibial cortex.[37,57,58] Repeated intra-articular entrapment of the IML during plantar flexion can produce thickening of the ligament, focal synovitis, and fibrosis.[57,58]

Imaging The diagnosis of posterior ankle impingement syndrome is based primarily on the patient's clinical history and physical examination, and is supported by radiographic and MR imaging findings.[44,46,56]

MR imaging MR imaging can specifically identify the wide range of pathology that may contribute to posterior ankle impingement and to rule out other causes of posterior ankle pain.

MR arthrography MR arthrography offers few advantages over conventional MR imaging in the assessment of posterior ankle impingement syndrome (**Figs. 16** and **17**).[1] MR arthrography is primarily useful for the diagnosis of uncommon cases of posterior impingement caused by the IML. The IML is often not well visualized on conventional MR imaging. MR arthrography improves the visualization of this ligament, which can readily be separated from the surrounding PTFL and the deeper fibers of the PITF or transverse ligament. Irregular focal or diffuse thickening of the intermalleolar ligament (see **Fig. 17**), and focal fibrosis or synovitis are the MR arthrographic findings frequently observed.[1]

Osteochondral and cartilage lesions of the talus

Prevalence, epidemiology, and definitions Chondral injuries are common in the ankle and predispose

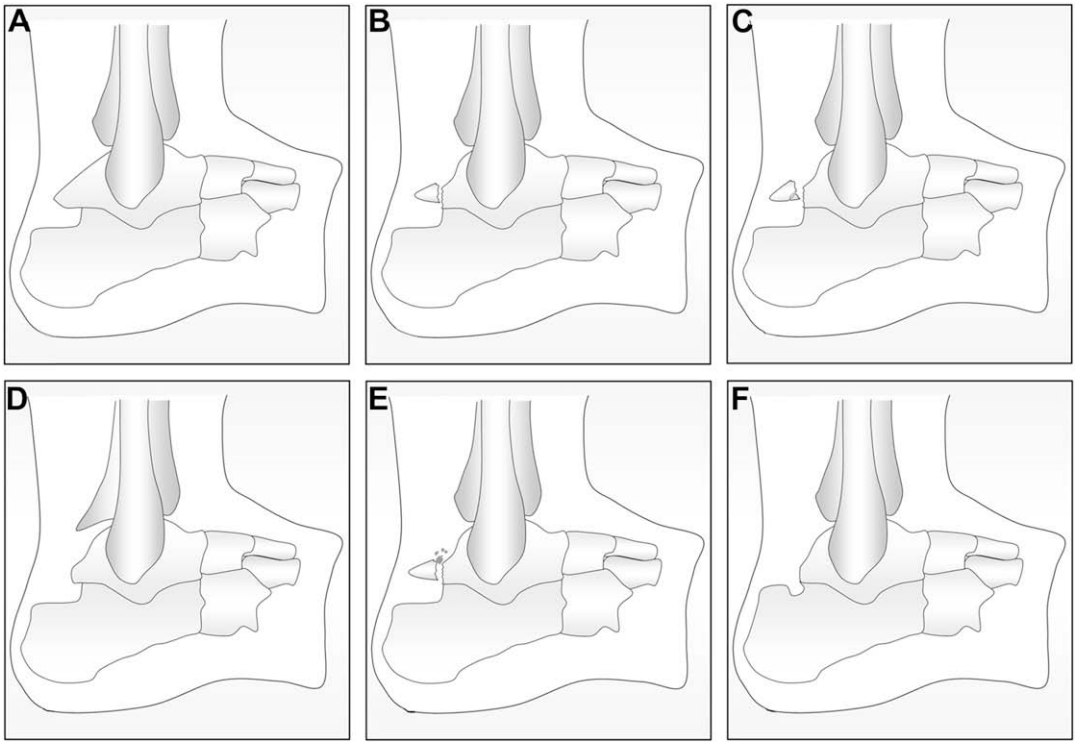

Fig. 15. Osseous anatomic structures involved in posterior impingement. (*A*) Stieda process. (*B*) Os trigonum. (*C*) Fractured lateral tubercle of the talus. (*D*) Prominent downslope of the posterior tibial articular surface. (*E*) Calcified inflammatory tissue. (*F*) Prominent superior surface of the calcaneal tuberosity.

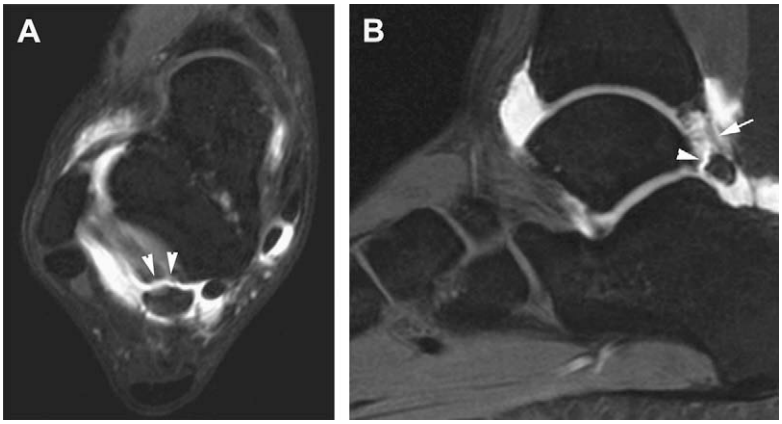

Fig. 16. Posterior impingement syndrome. (*A, B*) Axial and sagittal fat-suppressed MR arthrograms of the right ankle demonstrate irregularity of the os trigonum synchondrosis (*arrowheads*) and irregular fibrosis in the posterior recesses (*arrow in B*).

to development of degenerative arthritis. Osteochondral injuries reflect injury not only to the articular cartilage, but also the subchondral bone. "Osteochondral lesion of the talus" (OLT) is the accepted term for a variety of disorders including: osteochondritis dissecans, osteochondral fracture, transchondral fracture, and talar dome fracture.[59,60] OLT are more common in men than women and represent

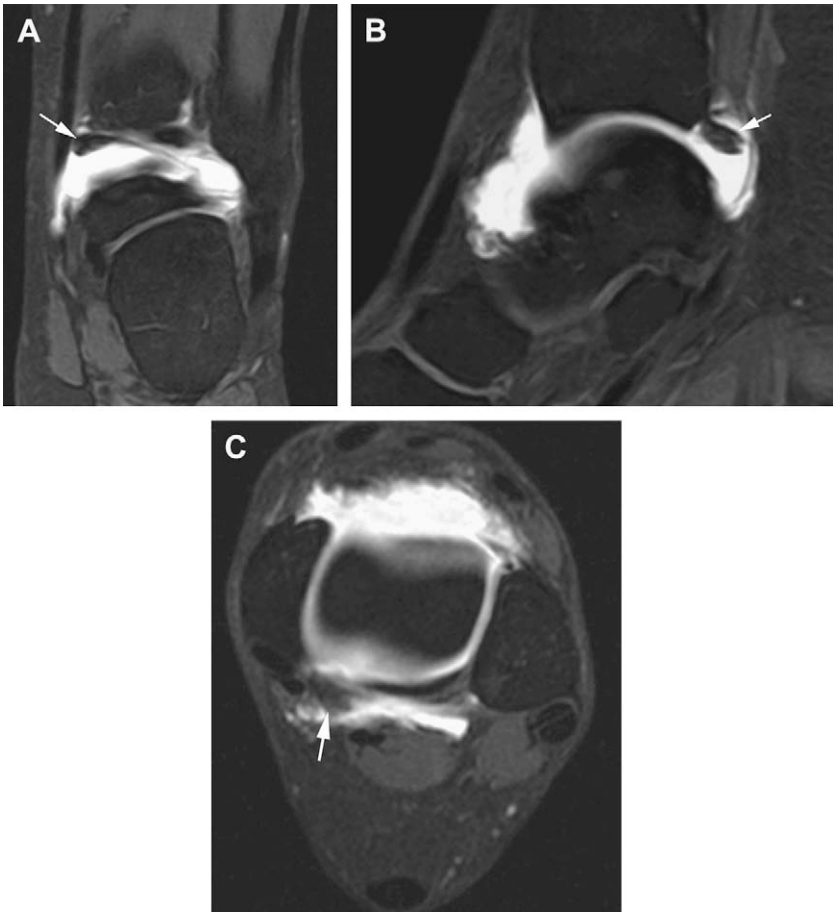

Fig. 17. Posterior impingement syndrome. (*A–C*) Coronal, sagittal, and axial fat-suppressed MR arthrograms of the left ankle show focal nodular thickening of the medial aspect of IML (*arrows*).

4% of all osteochondral lesions in the body. After the knee and elbow, the talus is the third most common location of osteochondral lesions.[59,60]

Medial and lateral aspects of the talar dome are involved in approximately 55% and 45% of the cases, respectively (**Fig. 18**). Lateral OLT are typically located over the anterolateral portion of the talar dome. Medial lesions are most commonly located over the posteromedial portion.[59,60]

Clinical symptoms and physical findings Osteochondral and chondral lesions of the talus usually manifest as persistent ankle pain ipsilateral to the lesion, accompanied by intermittent joint swelling, catching, and limitation of motion of the joint in the context of prior ankle inversion injury.[59,60]

Pathophysiology Lateral OLT are almost always associated with an acute traumatic episode and most probably represent true osteochondral or transchondral fractures, whereas patients with medial OLT usually do not have a clear recent trauma. Although trauma is the most common cause of OLT, ischemic necrosis, endocrine disorders, and genetic factors may have etiologic significance. In 10% to 25% of affected individuals, OLT is bilateral.[59,60]

The primary mechanism of injury is talar dome impaction due to ankle inversion. Lateral OLT results from inversion and dorsiflexion with impaction of the anterolateral aspect of the talar dome against the fibula. Traumatic medial OLT results from a combination of inversion, plantarflexion, and external rotation with impaction of the posteromedial tibia and medial talar margin.[59,60]

Imaging The Berndt and Harty classification schema[61] is the most widely accepted staging system for OLT (**Fig. 18**B). Stage I represents subchondral compression fracture. Stage II consists of a partially detached osteochondral fragment. In stage III, the osteochondral fragment is completely detached but not displaced from its donor site. In stage IV, the osteochondral fragment is detached and displaced.

Bilateral radiographs, including anteroposterior, lateral, and mortise views, should be the initial imaging method when OLT is suspected. Morphologically, lateral lesions tend to be shallower and more wafer shaped than medial lesions, which appear as deeper, cup-shaped defects.[60] It should be noted that radiographs are insensitive for detection of chondral injuries and relatively insensitive for detection of stage I and stage II OLT.

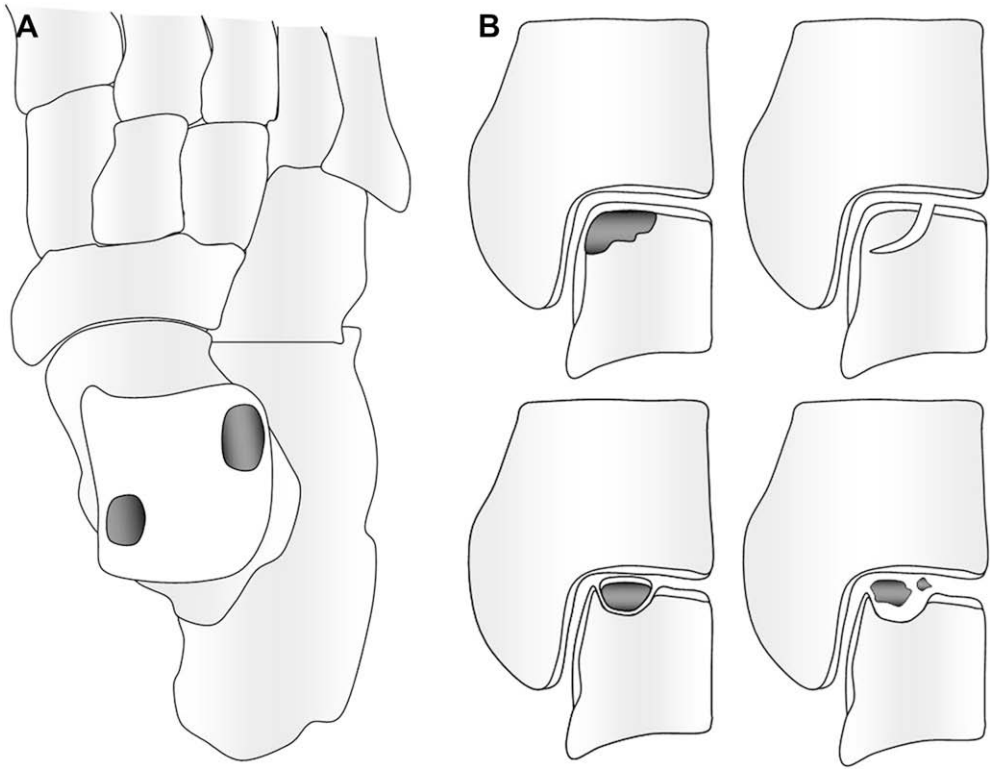

Fig. 18. Osteochondral lesions of the talus. (*A*) The main locations of osteochondral lesions of the talus and (*B*) diagram of Berndt and Harty classification system.

MR imaging MR imaging is sensitive for detecting and characterizing radiographically occult OLT, and permits assessment of the integrity of the overlying cartilage. MR imaging can also determine the viability of the osteochondral fragment. Necrotic fragments appear dark on both T1- and T2-weighted images and do not enhance after gadolinium administration.[23,33]

Multiple-pulse sequences are used for cartilage assessment with extremely variable reported sensitivity and specificity. For cartilage evaluation the following MR imaging, grading is most commonly used: grade I lesions MR images show abnormal intrachondral signal with smooth chondral surface and without alterations of the chondral thickness. Grade II lesions show mild surface irregularity with or without focal loss of less than 50% of the cartilage thickness. Severe surface irregularities with thinning of the cartilage thickness by more than 50% are present in grade III lesions and grade IV lesions consist of complete loss of articular cartilage with denuded subchondral bone.[5]

There is some controversy concerning the accuracy of MR imaging for assessing the stability of the osteochondral fragment.[62,63] Although arthroscopy remains the gold standard, MR imaging is an excellent predictor of fragment stability. MR imaging diagnosis of instability of osteochondral lesions of the talus has relied on the interface between the osteochondral fragment and the parent bone on T2-weighted images. A stable or healed osteochondral fragment is characterized by lack of high signal intensity at the interface between the lesion and the parent bone. The presence of a high signal line on T2-weighted images at the talar interface with the osteochondral fragment is the most reliable sign of instability.[63] It may represent granulation tissue or fluid. Usually, a moderately hyperintense interface, not as hyperintense as fluid, indicates the presence of fibrovascular granulation tissue or developing fibrocartilage. At this stage, the lesion is unstable but can heal after a period of non–weight bearing or internal fixation. If the interface is isointense with fluid or associated with cystic-appearing areas at the base of a nondisplaced lesion, surgery is indicated.

MR arthrography MR arthrography is more accurate than conventional MR imaging in the evaluation of articular cartilage, the assessment of stability of osteochondral lesions (**Fig. 19**), and the detection of intra-articular bodies.[1,2,64]

MR arthrography aids in prearthroscopic assessment, differentiating between stage II and stage III OLT by documenting intra-articular communication of fluid around the lesion.[1,5]

MR arthrography allows excellent delineation of the chondral surface and provides good discrimination of higher grade cartilaginous lesions (**Fig. 20**).[64] MR arthrography is superior to unenhanced MR imaging because fluid is forced into the chondral defects at the interface between the OLT and its donor site. MR arthrography can detect chondral lesions as small as 2 mm. It should be noted that grade I chondral lesions have no surface contour defect or irregularity and may not be detected with MR arthrography.[5,64]

Treatment

Treatment of osteochondral injuries Lesion stability determines treatment. In stable OLT (stage

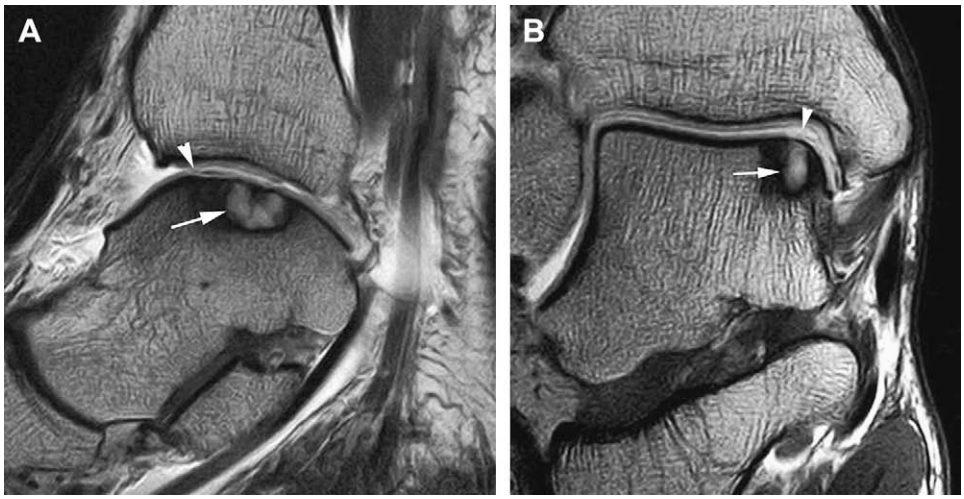

Fig. 19. Cystic osteochondral lesion of the talus. (*A, B*) Sagittal and coronal T1-weighted MR arthrograms of the right ankle demonstrate cystic medial osteochondral lesion of the talus (*arrows*). Note existence of cartilage detached flap (*arrowheads*).

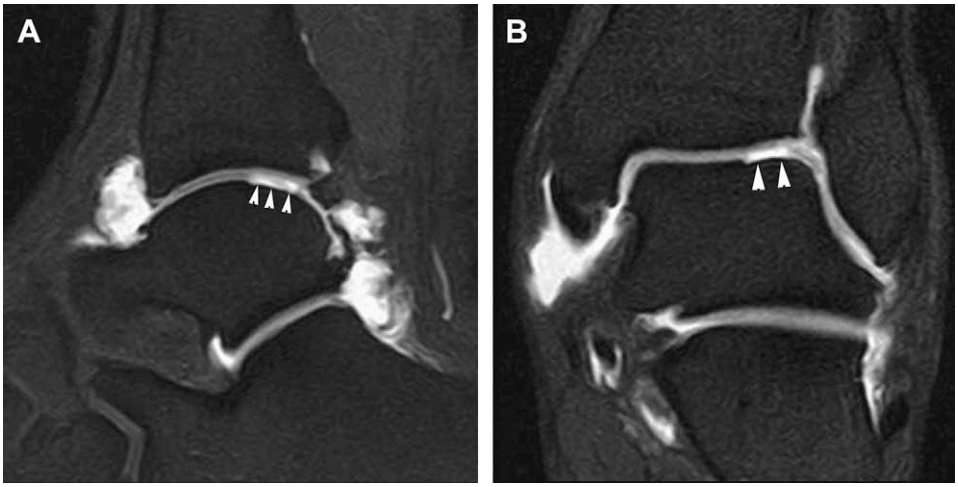

Fig. 20. Chondral grade IV lesion of the talar dome. (*A, B*) Sagittal and coronal fat-suppressed MR arthrograms of the left ankle show large cartilage defect (grade IV lesion) in the posterolateral aspect of the talar dome (*arrowheads*).

I and most stage II lesions) conservative treatment is recommended. Surgical treatment is advocated for unstable lesions, including stage IV and the majority of stage III lesions.[59,60,62]

Current principles of surgical treatment[65] fall into one of three categories: (1) loose body removal with or without stimulation of fibrocartilage growth (microfracture, curettage, abrasion, or transarticular drilling), (2) securing the OLT to the talar dome through retrograde drilling, bone grafting, or internal fixation, and (3) stimulating development of hyaline cartilage through osteochondral autografts, allografts, or cell culture.

Treatment of cartilage injuries As no stem cells are found within hyaline cartilage, the intrinsic repair capabilities of cartilage are limited. Many surgical repair techniques have been developed, with new cartilage-dedicated therapeutic strategies targeted at therapy for early stages of osteoarthritis. These strategies include: palliative (debridement or stabilization of loose articular cartilage), reparative (stimulation of repair from the subchondral bone, such as microfracturing), and restorative procedures (replacement of damaged cartilage; the most promising technique being cell transplantation–based repair).[62]

Imaging cartilage repair The advent of new procedures for repairing cartilage has increased the need for accurate noninvasive methods to objectively evaluate the success of repair. MR imaging is less invasive than arthroscopy, and allows a more comprehensive evaluation of repair tissue, from the articular surface of the joint to the bone–cartilage interface.[62] Despite the higher spatial resolution of new pulse sequences, higher field strength MR imaging, and promising new techniques that evaluate cartilage matrix characteristics, many authors[62,64] suggest that MR arthrography is superior to MR imaging because it allows a more accurate characterization of the overlying repair tissue (**Fig. 21**). MR arthrography is helpful in evaluating detachment of the graft, facilitated differentiation between delamination of the base of the graft, and normal high-signal-intensity repair tissue in the immediate postoperative period.[62]

Intra-articular loose bodies

Intra-articular loose bodies in the ankle joint may produce impingement symptoms. Loose bodies may be bone, cartilage, or bone and cartilage.[66]

Imaging is usually required to confirm the clinical diagnosis and localize the intra-articular loose bodies before surgery. Radiographs are useful only when calcified intra-articular bodies are present.

MR arthrography is the optimal imaging technique for detecting osseous and cartilaginous loose bodies with an accuracy of 92%, which is significantly better than MR imaging (57%–70%).[66] Air bubbles can mimic loose bodies on MR arthrography, but the distinction can usually be made by their nondependent position and typical appearance (see **Fig. 2**).[7–11]

Adhesive capsulitis

Prevalence, epidemiology, and definitions Adhesive capsulitis, also known as a frozen ankle, is posttraumatic stiffness of the ankle joint that can severely affect the patient's movement and ability

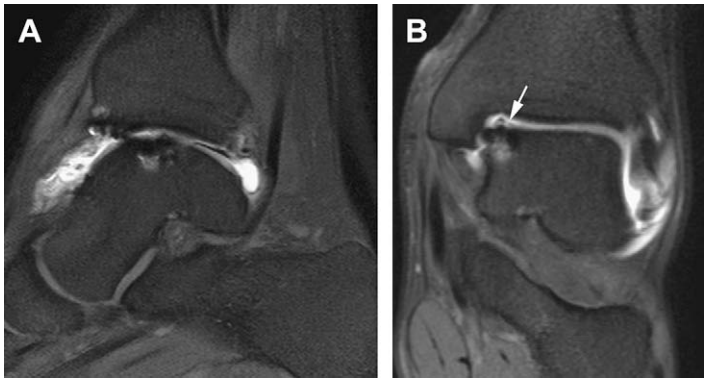

Fig. 21. Autologous osteochondral plug transfer in the medial talar dome. (*A, B*) Sagittal and coronal fat-suppressed MR arthrograms of the left ankle show good integration of osteochondral plug into the medial talar dome. The subchondral plate is flush, and there is only a slight cartilage fissure at the lateral margin of the graft (*arrow in B*).

to carry out activities of daily life. It can be caused by intra-articular or extra-articular pathology. It is a diagnostic and therapeutic challenge. Limited information concerning diagnosis and treatment is available in the musculoskeletal literature. Although the incidence of ankle adhesive capsulitis is unknown, some reports suggest that it may be more frequent than recognized.[67,68]

Clinical symptoms and physical findings Clinically, patients present with ankle pain, stiffness, and swelling. Calf muscle atrophy also may be present. Symptoms may start immediately after immobilization or several months after a traumatic ankle injury. Physical examination reveals decreased range of motion of the ankle joint, with limitation of both dorsi and plantar flexion because the entire capsule is involved.[67,68]

Pathophysiology The exact pathophysiology of posttraumatic adhesive capsulitis is unknown.[67,68] Although all reported patients had traumatic ankle joint injury, a specific etiology has not been yet identified. Trauma may occur in the form of a single catastrophic event or repetitive minor injuries. Immobilization after trauma also may play a role in promoting fibrosis and subsequent progression to adhesive capsulitis. Although it has only been reported as a consequence of trauma, it is possible that nontraumatic ankle pain may be caused by adhesive capsulitis and may be secondary to other etiologies such as inflammatory synovitis or degenerative joint disease.[67,68]

Shoulder adhesive capsulitis is more common than in the ankle or other joints and has been extensively studied, demonstrating association with other conditions including diabetes, hypothyroidism, and hyperthyroidism. Pathologic studies indicate that the entire shoulder joint capsule is involved (**Fig. 22**), not just the site of the initial injury. The primary lesion occurs in the fibrous layer

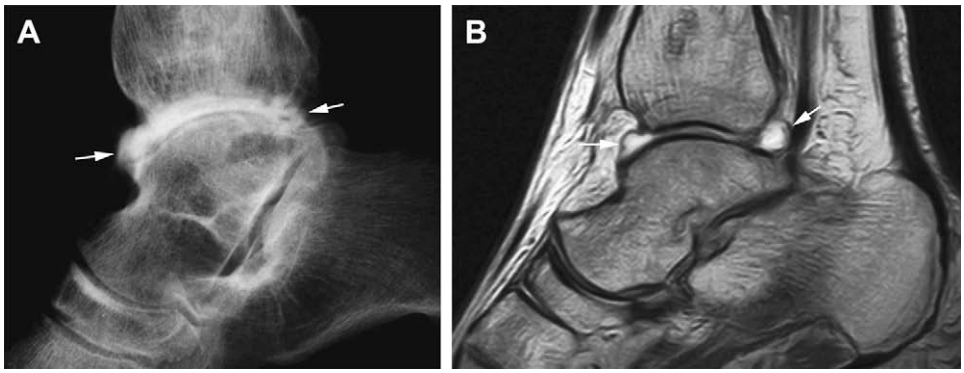

Fig. 22. Adhesive capsulitis of tibiotalar joint. (*A*) Lateral ankle arthrogram and (*B*) sagittal T1-weighted MR arthrogram of the right ankle in a patient previously surgically treated for bimalleolar fracture show restricted filling of the anterior and posterior capsular recesses (*arrows*). A decreased joint volume (4 mL) was encountered during arthrography as well.

of the capsule that becomes thickened by dense compact bundles of connective tissue containing new fibrocytes.

Imaging

Classically, conventional arthrography was used for diagnosis of adhesive capsulitis of the ankle. Three arthrographic criteria were described: (1) reduction of joint volume from the normal 10 to 25 mL, to 3 to 5 mL (**Fig. 22**A), (2) high intra-articular pressure with back-flow of the contrast material, and (3) obliteration of the anterior, posterior, and syndesmotic recesses of the ankle.[67,68] Standard three-view ankle radiographs were usually nonspecific. The value of CT and MR imaging has not been described.

The diagnostic value of MR imaging for ankle adhesive capsulitis is not clear, but remains an important tool for ruling out other causes of ankle pain and stiffness.

MR arthrography is currently the best method of diagnosis. It combines the advantages of MR imaging with conventional ankle arthrography criteria. MR arthrographic findings include: decrease in joint capacity, obliteration of normal joint recesses, and capsular thickening (**Fig. 22**B).[1]

Treatment

Treatment of ankle adhesive capsulitis has not been reported in a significant number of patients, and there are no long-term outcome data. Range-of-motion ankle exercise programs and adjunctive therapies with or without intra-articular injection of steroids usually improve symptoms, but the long-term benefits are not documented. Arthroscopic synovectomy is potentially an effective treatment for posttraumatic ankle adhesive capsulitis.[67,68] Therapeutic effects may result from excision of the major intra-articular adhesions by partial synovectomy and removal of scar tissue. This is supported by improved range of ankle movement after ankle arthroscopy.

SUMMARY

MR arthrography has become an important tool for the assessment of a wide variety of joint disorders. MR arthrography may facilitate the evaluation of patients with suspected intra-articular pathology in whom conventional MR imaging is not sufficient for obtaining an adequate diagnosis, and is thus useful for planning therapy. MR arthrography is an easy and safe procedure with a very low rate of complications. Indirect MR arthrography is a useful adjunct to conventional MR imaging and may be preferable to direct MR arthrography in cases where an invasive procedure is contraindicated or when fluoroscopy is not available.

In patients with a history of ankle sprains, chronic pain or instability can limit activity and affects up to 20% to 40% of patients. When conservative treatment has failed in these patients and surgical treatment is contemplated, MR arthrography of the ankle permits accurate diagnosis of ligament injuries, and other frequently associated pathology such as impingement syndromes, chondral and osteochondral injuries, and intra-articular loose bodies with greater reliability as compared with conventional MR imaging.

MR arthrography plays an important role in the diagnosis and staging of chondral and osteochondral injuries of the talar dome, and in monitoring the evolution of the different treatments available today.

Adhesive capsulitis or frozen ankle is a related posttraumatic disorder that severely limits ankle motion and may occur more frequently than recognized. MR arthrography of the ankle is a reliable way to diagnose this condition.

REFERENCES

1. Cerezal L, Abascal F, Garcia-Valtuille R, et al. Ankle MR arthrography: how, why, when. Radiol Clin North Am 2005;43(4):693–707.
2. Cerezal L, Abascal F, Canga A, et al. Magnetic resonance arthrography indications and technique (II). Lower limb. Radiologia 2006;48(6):357–68.
3. Chandnani VP, Harper MT, Ficke JR, et al. Chronic ankle instability: evaluation with MR arthrography, MR imaging, and stress radiography. Radiology 1994;192(1):189–94.
4. Helgason JW, Chandnani VP. MR arthrography of the ankle. Radiol Clin North Am 1998;36(4):729–38.
5. Kramer J, Recht MP. MR arthrography of the lower extremity. Radiol Clin North Am 2002;40(5):1121–32.
6. Elentuck D, Palmer WE. Direct magnetic resonance arthrography. Eur Radiol 2004;14(11):1956–67.
7. Grainger AJ, Elliott JM, Campbell RS, et al. Direct MR arthrography: a review of current use. Clin Radiol 2000;55(3):163–76.
8. Osinski T, Malfair D, Steinbach L. Magnetic resonance arthrography. Orthop Clin North Am 2006; 37(3):299–319.
9. Peh WC, Cassar-Pullicino VN. Magnetic resonance arthrography: current status. Clin Radiol 1999; 54(9):575–87.
10. Sahin G, Demirtas M. An overview of MR arthrography with emphasis on the current technique and applicational hints and tips. Eur J Radiol 2006;58(3):416–30.
11. Steinbach LS, Palmer WE, Schweitzer ME. Special focus session. MR arthrography. Radiographics 2002;22(5):1223–46.

12. Brown RR, Clarke DW, Daffner RH. Is a mixture of gadolinium and iodinated contrast material safe during MR arthrography? AJR Am J Roentgenol 2000; 175(4):1087–90.
13. Schulte-Altedorneburg G, Gebhard M, Wohlgemuth WA, et al. MR arthrography: pharmacology, efficacy and safety in clinical trials. Skeletal Radiol 2003;32(1):1–12.
14. Robbins MI, Anzilotti KF Jr, Katz LD, et al. Patient perception of magnetic resonance arthrography. Skeletal Radiol 2000;29(5):265–9.
15. Wagner SC, Schweitzer ME, Weishaupt D. Temporal behavior of intra-articular gadolinium. J Comput Assist Tomogr 2001;25(5):661–70.
16. Lee SH, Jacobson J, Trudell D, et al. Ligaments of the ankle: normal anatomy with MR arthrography. J Comput Assist Tomogr 1998;22(5):807–13.
17. Hodler J. Technical errors in MR arthrography. Skeletal Radiol 2008;37(1):9–18.
18. Bergin D, Schweitzer ME. Indirect magnetic resonance arthrography. Skeletal Radiol 2003;32(10): 551–8.
19. Morrison WB. Indirect MR arthrography: concepts and controversies. Semin Musculoskelet Radiol 2005;9(2):125–34.
20. Schweitzer ME, Natale P, Winalski CS, et al. Indirect wrist MR arthrography: the effects of passive motion versus active exercise. Skeletal Radiol 2000; 29(1):10–4.
21. Vahlensieck M, Peterfy CG, Wischer T, et al. Indirect MR arthrography: optimization and clinical applications. Radiology 1996;200(1):249–54.
22. Zoga AC, Schweitzer ME. Indirect magnetic resonance arthrography: applications in sports imaging. Top Magn Reson Imaging 2003;14(1):25–33.
23. Bencardino J, Rosenberg ZS, Delfaut E. MR imaging in sports injuries of the foot and ankle. Magn Reson Imaging Clin N Am 1999;7(1):131–49.
24. Cheung Y, Rosenberg ZS. MR imaging of ligamentous abnormalities of the ankle and foot. Magn Reson Imaging Clin N Am 2001;9(3):507–31.
25. Garrick JG, Requa RK. The epidemiology of foot and ankle injuries in sports. Clin Sports Med 1988;7(1): 29–36.
26. Linklater J. Ligamentous, chondral, and osteochondral ankle injuries in athletes. Semin Musculoskelet Radiol 2004;8(1):81–98.
27. Gerber JP, Williams GN, Scoville CR, et al. Persistent disability associated with ankle sprains: a prospective examination of an athletic population. Foot Ankle Int 1998;19(10):653–60.
28. DIGiovanni BF, Fraga CJ, Cohen BE, et al. Associated injuries found in chronic lateral ankle instability. Foot Ankle Int 2000;21(10):809–15.
29. Renstrom PA. Persistently painful sprained ankle. J Am Acad Orthop Surg 1994;2(5):270–80.
30. Krips R, de Vries J, van Dijk CN. Ankle instability. Foot Ankle Clin 2006;11(2):311–29.
31. Colville MR. Surgical treatment of the unstable ankle. J Am Acad Orthop Surg 1998;6(6):368–77.
32. Peters JW, Trevino SG, Renstrom PA. Chronic lateral ankle instability. Foot Ankle 1991;12(3):182–91.
33. Rosenberg ZS, Beltran J, Bencardino JT. From the RSNA Refresher Courses. Radiological Society of North America. MR imaging of the ankle and foot. Radiographics 2000;20(Suppl):153–79.
34. Espinosa N, Smerek J, Kadakia AR, et al. Operative management of ankle instability: reconstruction with open and percutaneous methods. Foot Ankle Clin 2006;11(3):547–65.
35. Espinosa N, Smerek JP, Myerson MS. Acute and chronic syndesmosis injuries: pathomechanisms, diagnosis and management. Foot Ankle Clin 2006; 11(3):639–57.
36. Brown KW, Morrison WB, Schweitzer ME, et al. MRI findings associated with distal tibiofibular syndesmosis injury. AJR Am J Roentgenol 2004;182(1): 131–6.
37. Golano P, Vega J, Perez-Carro L, et al. Ankle anatomy for the arthroscopist. Part II: role of the ankle ligaments in soft tissue impingement. Foot Ankle Clin 2006;11(2):275–96.
38. Nikolopoulos CE, Tsirikos AI, Sourmelis S, et al. The accessory anteroinferior tibiofibular ligament as a cause of talar impingement: a cadaveric study. Am J Sports Med 2004;32(2):389–95.
39. Bassett FH III, Gates HS III, Billys JB, et al. Talar impingement by the anteroinferior tibiofibular ligament. A cause of chronic pain in the ankle after inversion sprain. J Bone Joint Surg Am 1990;72(1):55–9.
40. Oae K, Takao M, Naito K, et al. Injury of the tibiofibular syndesmosis: value of MR imaging for diagnosis. Radiology 2003;227(1):155–61.
41. Hintermann B, Knupp M, Pagenstert GI. Deltoid ligament injuries: diagnosis and management. Foot Ankle Clin 2006;11(3):625–37.
42. van Dijk CN, Bossuyt PM, Marti RK. Medial ankle pain after lateral ligament rupture. J Bone Joint Surg Br 1996;78(4):562–7.
43. Milner CE, Soames RW. The medial collateral ligaments of the human ankle joint: anatomical variations. Foot Ankle Int 1998;19(5):289–92.
44. Cerezal L, Abascal F, Canga A, et al. MR imaging of ankle impingement syndromes. AJR Am J Roentgenol 2003;181(2):551–9.
45. Umans HR, Cerezal L. Anterior ankle impingement syndromes. Semin Musculoskelet Radiol 2008; 12(2):146–53.
46. Robinson P, White LM. Soft-tissue and osseous impingement syndromes of the ankle: role of imaging in diagnosis and management. Radiographics 2002;22(6):1457–69.

47. Umans H. Ankle impingement syndromes. Semin Musculoskelet Radiol 2002;6(2):133–9.
48. Sanders TG, Rathur SK. Impingement syndromes of the ankle. Magn Reson Imaging Clin N Am 2008; 16(1):29–38.
49. Hauger O, Moinard M, Lasalarie JC, et al. Anterolateral compartment of the ankle in the lateral impingement syndrome: appearance on CT arthrography. AJR Am J Roentgenol 1999;173(3):685–90.
50. Rubin DA, Tishkoff NW, Britton CA, et al. Anterolateral soft-tissue impingement in the ankle: diagnosis using MR imaging. AJR Am J Roentgenol 1997; 169(3):829–35.
51. Wolin I, Glassman F, Sideman S, et al. Internal derangement of the talofibular component of the ankle. Surg Gynecol Obstet 1950;91(2):193–200.
52. Robinson P, White LM, Salonen DC, et al. Anterolateral ankle impingement: MR arthrographic assessment of the anterolateral recess. Radiology 2001; 221(1):186–90.
53. Tol JL, van Dijk CN. Anterior ankle impingement. Foot Ankle Clin 2006;11(2):297–310.
54. Paterson RS, Brown JN. The posteromedial impingement lesion of the ankle. A series of six cases. Am J Sports Med 2001;29(5):550–7.
55. Robinson P, White LM, Salonen D, et al. Anteromedial impingement of the ankle: using MR arthrography to assess the anteromedial recess. AJR Am J Roentgenol 2002;178(3):601–4.
56. Bureau NJ, Cardinal E, Hobden R, et al. Posterior ankle impingement syndrome: MR imaging findings in seven patients. Radiology 2000;215(2):497–503.
57. Fiorella D, Helms CA, Nunley JA. The MR imaging features of the posterior intermalleolar ligament in patients with posterior impingement syndrome of the ankle. Skeletal Radiol 1999;28(10):573–6.
58. Rosenberg ZS, Cheung YY, Beltran J, et al. Posterior intermalleolar ligament of the ankle: normal anatomy and MR imaging features. AJR Am J Roentgenol 1995;165(2):387–90.
59. Stone JW. Osteochondral lesions of the talar dome. Am J Orthop 2007;36(12):643–6.
60. Schachter AK, Chen AL, Reddy PD, et al. Osteochondral lesions of the talus. J Am Acad Orthop Surg 2005;13(3):152–8.
61. Berndt AL, Harty M. Transchondral fractures (osteochondritis dissecans) of the talus. Am J Orthop 1959;41-A:988–1020.
62. Choi YS, Potter HG, Chun TJ. MR imaging of cartilage repair in the knee and ankle. Radiographics 2008;28(4):1043–59.
63. De Smet AA, Fisher DR, Burnstein MI, et al. Value of MR imaging in staging osteochondral lesions of the talus (osteochondritis dissecans): results in 14 patients. AJR Am J Roentgenol 1990;154(3):555–8.
64. Schmid MR, Pfirrmann CW, Hodler J, et al. Cartilage lesions in the ankle joint: comparison of MR arthrography and CT arthrography. Skeletal Radiol 2003; 32(5):259–65.
65. Zengerink M, Szerb I, Hangody L, et al. Current concepts: treatment of osteochondral ankle defects. Foot Ankle Clin 2006;11(2):331–59.
66. Brossmann J, Preidler KW, Daenen B, et al. Imaging of osseous and cartilaginous intra-articular bodies in the knee: comparison of MR imaging and MR arthrography with CT and CT arthrography in cadavers. Radiology 1996;200(2):509–17.
67. Cui Q, Milbrandt T, Millington S, et al. Treatment of posttraumatic adhesive capsulitis of the ankle: a case series. Foot Ankle Int 2005;26(8):602–6.
68. Lui TH, Chan WK, Chan KB. The arthroscopic management of frozen ankle. Arthroscopy 2006;22(3):283–6.