

Acute Hand Compartment Syndromes after Closed Crush: A Reappraisal

Francisco del Piñal, M.D., Dr. Med., Francisco Herrero, M.D., Emilia Jado, M.D.,
Francisco J. García-Bernal, M.D., Dr. Med., and Luis Cerezal, M.D.

Santander, Spain

Severe crush to the hand is associated with a poor prognosis. The authors investigated the hypothesis that compartment syndrome complicates such injuries. From 1996 to 2000, the authors retrospectively identified 11 patients who, after sustaining a closed crush injury, developed acute hand compartment syndrome. Diagnosis was made on clinical grounds in two patients (the intracompartmental pressure was not measured) and after clinical examination plus measurement of intracompartmental pressure in nine patients. In all cases, the muscle burst out once the fascia was released from the affected compartment. Clinical clues to elicit the diagnoses were massive hand swelling and tenseness to palpation. Classic symptoms, such as excruciating pain, were absent or their intensity was attributed to the trauma event (in six patients). Classic signs such as intrinsic muscle minus position and pain on stretching were absent in six and three patients, respectively. In addition, the latter stretch test could not be properly judged in five more patients because of interference by the associated injuries. None of the patients developed contracture or sequela that could be attributed to compartment syndrome. On the basis of this experience, it was concluded that crush injury does not in itself carry a poor functional prognosis, provided that attention is paid to the often-concomitant compartment syndrome. Elevated subfascial pressure may be present despite the absence of classic signs and symptoms. (*Plast. Reconstr. Surg.* 110: 1232, 2002.)

Severe crush to the hand has traditionally been associated with a poor functional outcome.¹⁻⁴ It should be noted, however, that failure to release swelling muscles confined in closed osteofascial compartments invariably causes muscle death and, subsequently, contracture.⁵ Irreversible damage to the muscle enclosed in the osteofascial compartments of the hand causes ischemic retraction of the

intrinsic muscles, known as Finochietto's contracture.^{6,7}

Zancolli^{6,8} identified three types of ischemic contracture involving the hand: generalized, which affects all compartments of the hand; localized, which affects only a group of compartments, mostly referring to the radial-thenar; and atypical, which affects single or unevenly distributed compartments. The syndrome is characterized by flexion at the metacarpophalangeal joint, extension of the proximal and distal interphalangeal joints of the fingers, and retropulsion or adduction-palmar abduction of the thumb (in the palm).⁶⁻¹⁰

In this study, we investigated the hypothesis that acute compartment syndrome surreptitiously aggravates crush injuries to the hand. Furthermore, we emphasize the need for the surgeon to actively look for compartment syndrome and to measure the intracompartmental pressure, because the clinical signs may be scant and nonpathognomonic.

PATIENTS AND METHODS

Over a 5-year period (January of 1996 to December of 2000), the authors retrospectively identified 11 patients who required urgent surgical decompression of the intrinsic muscles (all or some) of the hand after sustaining a closed crush. All patients in the study group were male, 20 to 57 years of age, involved in heavy labor, and covered under workers' compensation. Not included in this study were those patients with open crush injuries whose

From Instituto de Cirugía Plástica y de la Mano, Hospital Mutua Montañesa, and Clínica Mompía. Received for publication October 26, 2001; revised January 28, 2002.

Presented at the 10th Kleinert Society Clinical Reunion, Louisville, Kentucky, September 30 to October 3, 2001.

DOI: 10.1097/01.PRS.0000025183.78057.9B

compartments were spontaneously released by the injury and required further release of the same or neighboring compartments. The presence of ragged skin flaps was not a reason for exclusion provided that the underlying compartments remained intact.

Patients were recruited from two casualty centers that, between them, receive approximately 600 hand injuries per year, most work-related. In every case, one (or both) of the two first surgeons were involved in the assessment and grading of the signs and symptoms referred to in Table I. The diagnosis of compartment syndrome was suspected on the basis of marked swelling, disproportionate pain spontaneously or elicited during the intrinsic test,¹¹ intrinsic minus stance, hypoesthesias or paresthesias in some or all fingers, and tenseness on palpation. In addition, a low-threshold policy was maintained in measuring intracompartmental pressure in any patient whose hand was swollen, particularly if the mechanism of injury was a crush. A hand-held digital transducer monitor designed for this purpose (Striker Surgical Co., Kalamazoo, Mich.) was used. Measurements were performed as suggested by the manufacturer, and 30 mmHg was selected as the upper normal limit.¹²⁻¹⁴

Once the diagnosis was made, either on clinical grounds in two patients (the intracompartmental pressure was not measured), or on clinical plus recording intracompartmental pressure in nine, surgery was performed without delay (<6 hours after the traumatic event in all except for case 11, who underwent surgery at 12 hours). Release of the affected compartments was undertaken by means of one thenar, one hypothenar, and two dorsal incisions if all compartments were affected (generalized form) or as required in more localized forms. Detailed information on the surgical technique can be found in the classic textbooks.^{15,16} The carpal tunnel was released only if preoperatively the patient referred paresthesias in the median nerve distribution and/or the tissue pressure in the carpal compartment was higher than 30 mmHg. In three patients, release of the volar antebrachial fascia was undertaken after opening the carpal tunnel (see Discussion section). A final patient, who sustained a crush to the hand and forearm, required treatment for an associated acute volar forearm compartment (patient 11).

Closure of the carpal canal was done primarily in every case to protect the median nerve,

TABLE I
Assessment and Grading of Signs and Symptoms of Compartment Syndrome

Patient/Age/ Dominance	Compartment Affected*	Pain†	Swelling‡	Intrinsic Minus Position	Paresthesias/ Hypoesthesia	Pain on Stretch Test§	Compartment Tenseness†	Associated Injuries‡	ICP/Compartment§
1/26/ND	L	++	+++	No	No		+++	1st MPJ dislocation	50/thenar
2/57/D	L	+++	+++	No	Thumb		+++	1st MPJ Fx/thumb ischemic	Not done
3/46/ND	G	++	+++	Yes	No		+++	Comminuted Fx MPJ 2-5	73/hypothenar
4/45/ND	A	++	+++	No	No	+++	+++	None	98/2nd web space
5/24/D	G+ACT+DTF	++	+++	Yes	Median	+++	+++	Acute scapho-lunate dissociation	60/carpal tunnel
6/30/ND	G+ACT+DTF	++	+++	Yes	Median	++	+++	Intraarticular distal radius Fx	58/thenar
7/31/ND	G+ACT	++	+++	Yes	Median	+++	+++	None	Not done
8/24/D	G+ACT+DTF	+++	+++	Yes	Median		+++	Fx dislocation CMC joint 1-5	95/thenar
9/32/D	L+ACT	+++	+++	No	Third finger	++	+++	None	80/thenar
10/20/D	G+ACT	+++	+++	No	Median + ulnar		+++	1 MT Fx/3-5 Fx-dislocated CMC	66/1st web space
11/52/D	A+ACT+VF	++	++	No	Median + ulnar	+	+++	Intraarticular distal radius Fx	42/thenar¶

* L, localized hand compartment; G, generalized hand compartment; A, atypical hand compartment; ACT, acute carpal tunnel; DTF, distal third of the forearm; VF, full volar forearm.

† 0, normal to 4+, maximum.

‡ MPJ, metacarpophalangeal joint; Fx, fracture; CMC, carpal metacarpal; MT, metatarsal.

§ ICP/Comp, intracompartmental pressure in mmHg and recorded values in the most affected compartment.

|| Difficult to assess because of the associated injuries.

¶ In this patient the maximal pressure was at the volar forearm (48 mmHg).

and efforts were made to attempt primary skin closure, or to mobilize local tissues, when necessary to protect underlying synthesis material. The rest of the wounds were left open to close secondarily (at approximately 1 week) or to receive a skin graft as required.

Associated injuries were common (Table I) and, as stated above, some patients presented bruised and ragged flaps that at times required secondary skin grafts. Losses of muscle mass secondary to the crush event were seen frequently and were debrided.

At the latest follow-up, the patients were evaluated for intrinsic muscle tightness, including the Finochietto-Bunnell test,^{6,9} and were asked to actively place their fingers in intrinsic plus and minus (hook) to assess the contraction and gliding of the interossei. The width and suppleness of the first web was compared with that of the normal side. The patients were questioned in relation to pain, paresthesias, or diminished sensation in the median or ulnar nerve distribution. Range of motion and grip strength were also studied but were found to be related to the associated injuries and so were disregarded. The loss of muscle mass occasionally noted at the time of debridement also complicated the results.

RESULTS

Eleven patients were diagnosed with acute hand compartment syndrome: six had the generalized form; three had the localized form (in every case affecting the thenar and first web space muscles, and in two cases also affecting the second web space muscles); and two had the atypical form (case 4, the second and third web spaces muscles; case 11, the lateral thenar and hypothenar muscles). Associated compartment syndromes included acute carpal tunnel (seven patients), distal third of the forearm (three patients), and volar forearm (one patient) (Table I).

All patients were evaluated at a minimum of 6 months (range, 6 months to 4½ years). At the latest follow-up, all were able to perform the intrinsic plus and minus actively without difficulty except for patients 3 and 4. Patient 3 had generalized adhesions of the extensor tendons over the proximal phalanx fractures, which limited his ability to perform the intrinsic minus test. Patient 4 had limited range of motion in the index finger after a malunited proximal phalanx fracture he sustained 2 years earlier; he had no additional limitation after

the current injury. The width of the first web was comparable with that of the normal side in all patients. No sensory loss was reported at the latest follow-up, and two-point discrimination was comparable with that of the normal side. Patient 5, however, had hypesthesia in the median territory, which slowly improved to normal over a 3-month period. In this patient, during carpal tunnel release the median nerve was found to be hemorrhagic (possibly because of the traumatic event), and epineurotomy and hematoma debridement were performed.

All but two patients returned to their preinjury heavy-labor jobs. Patient 3, a miner, rejected a tenolysis of the extensor tendons and retired. Patient 6, a mason, complained of wrist pain secondary to concomitant intraarticular distal radius fracture; this patient is currently unemployed and pursuing litigation.

DISCUSSION

Multiple etiologic causes have been implicated in Finochietto's ischemic retraction: crush,^{6,9} tight hand casts,⁹ proximal arterial injuries,⁹ burns,¹⁷ massive extravasation from arterial or venous lines,¹⁸ and others. From our investigations and clinical experience, we believe that three issues deserve discussion: (1) frequency (or rarity in the setting of crush injury to the hand), (2) clues for diagnosis, and (3) surgical treatment.

Frequency

Eleven patients had pathologic elevation of the intracompartmental pressure or a clinically apparent acute hand compartment syndrome during the study period; in all cases the muscle burst out once the fascia was released. This figure is high if one considers the scant literature on the subject^{11,18-21} and the low frequency reported in large trauma centers.²² Unfortunately, from our study we cannot infer a risk factor for a compartment syndrome to develop after severe crush.

Persistent joint contractures and stiffness are sometimes seen after severe crush injury to the hand. In our experience, the frequency of elevated compartment pressures after crush injuries raises two questions: (1) Are mild (or severe) forms of untreated compartment syndrome involved in the crippling sequelae of the crushed hand? (2) Could concomitant prophylactic release of the hand compartments improve the end result?

The surgeon should not expect to find the

classic intrinsic plus stance, as seen after ischemic contracture secondary to proximal vascular injuries or burns, after a crush injury to the hand. In the latter, the scarring in and around the intrinsic muscles, tendons, and digital joints, and the deformities secondary to fractures, also play a role in the hand stance. Nemethi² and Wolfort et al.²¹ already raised the point that ischemic contracture of the intrinsic muscles could be behind the crippled crushed hand. This hypothesis would explain the apparent rarity of the syndrome and the poor prognosis of the crushed hand. Also, it would illustrate why, when releasing first web contrac-

ture in patients with a crush injury, the first dorsal interosseus muscle and adductor are replaced by scar tissue (Fig. 1, *above*), whereas when the cause of the first web contracture is a burn or late-stage reflex sympathetic dystrophy, the fascia is tight but normal muscle is underneath (Fig. 1, *below*).

Our results support that crush injury does not always result in a permanently crippled hand: nine of our patients returned to their previous work despite all being covered under workers' compensation. Immediate fasciotomies do play a major role, and this indirectly answers the second question above.

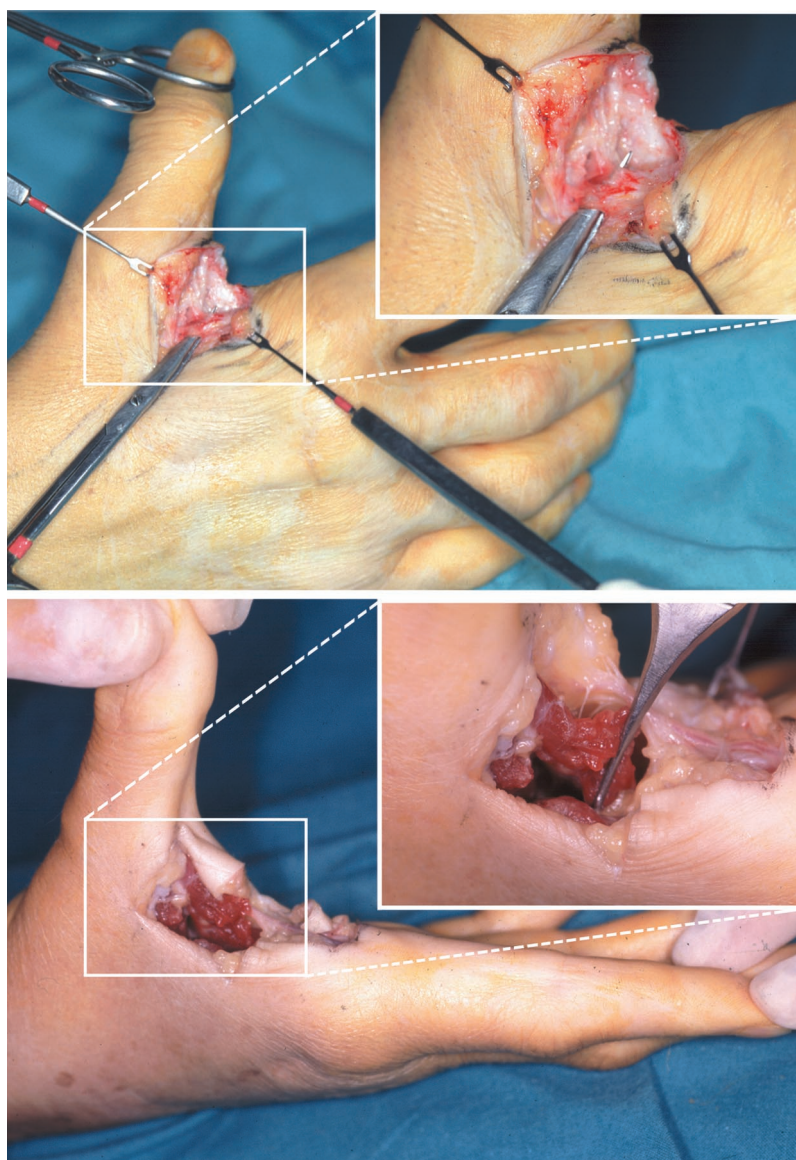


FIG. 1. (*Above*) During the first web contracture release, scar tissue can be seen in this patient, who suffered a crush to his hand 1 year previously. (*Below*) In another patient with a first web contracture after reflex sympathetic dystrophy, normal muscle is seen when the skin and fascia are excised.

Clues for Diagnosis

Spinner et al.,¹¹ in their classic 1972 article, comment, "A reliable diagnostic harbinger of an impending ischemic contracture of the hand is the triad of (1) pain, (2) paralysis, and (3) increasing pain when passively stretching the involved intrinsic muscle."

The presence of severe pain has been engraved in the surgeon's mind as a clue to making the diagnoses of compartment syndrome despite that prominent authors in the field have found this symptom to be unreliable.^{13,23-27} In our

series, the pain reported by the patients could be easily explained by the traumatic event in six of them. The intrinsic stretch test^{11,21} was at times impossible to perform because of the associated injuries (Table I), and the elicited pain was difficult to discern from that secondary to muscular contusion²⁸ in several more of the cases. Palsy is agreed to be too late a sign.²⁹

Spinner et al.¹¹ further stated, "The hand is usually grossly edematous. . . in the intrinsic minus posture." The intrinsic minus stance has been considered diagnostic of acute hand com-

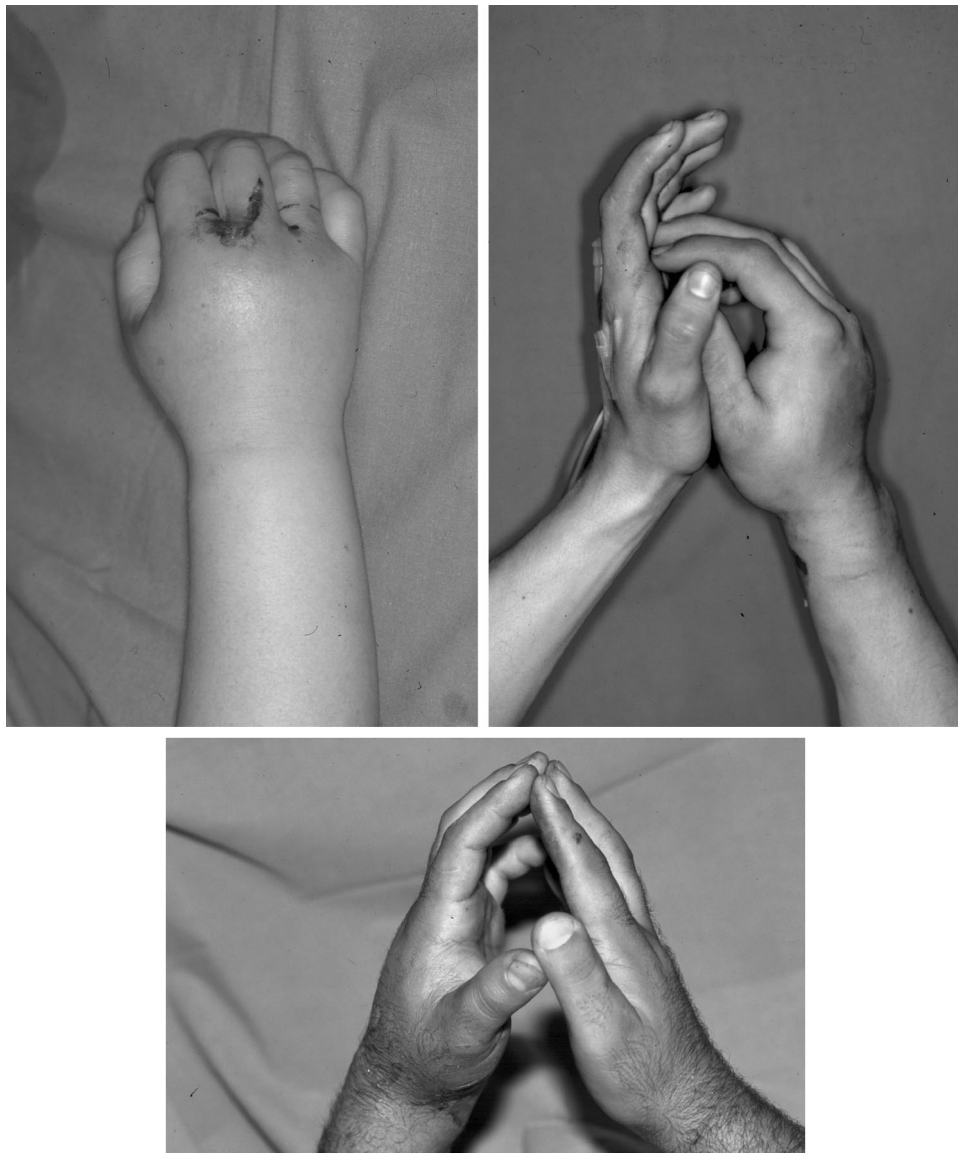

FIG. 2. Poor correlation among hand swelling, intrinsic minus posture, and intracompartmental pressures can be seen in these examples. (Above, left) Severe swelling, intrinsic minus posture, and intracompartmental pressure of 13 mmHg. (Above, right) Severe swelling, intrinsic plus position, and intracompartmental pressure of 66 mmHg (case 10). (Below) Printer roller injury: severe swelling, mild intrinsic minus stance, and intracompartmental pressure of 15 mmHg.

partment syndrome^{11,18,21,30}; however, we have found this to be not always so (Fig. 2), particularly when only the radial part of the hand is affected. By the same token, in our series severe swelling had a sensitivity of 100 percent, but the specificity was very low; we particularly emphasize the unspecificity of pitting edema¹⁰ compared with tense swelling.¹⁸ We not only had patients with massive edema and other conditions unrelated to crush, but we also had patients with crush plus edema and low compartmental pressure measurements (Fig. 2, *below*). Despite some exceptions,¹⁷ *tense swelling* was very helpful in reaching and following the diagnoses. Furthermore, and adding more confusion, severe swelling may cause an intrinsic minus stance by itself because of the elastic traction of the skin.³¹

Whitesides et al.,²³ Matsen et al.,³² and Mubarak et al.¹² presented reliable methods to record the interstitial tissue pressure for the diagnosis of an impending compartment syndrome. However, marked differences exist as to the threshold value for performing a fasciotomy, ranging from an absolute 15 mmHg¹⁸ to 40 to 50 mmHg (or 20 mmHg below diastolic).²³ We choose 30 mmHg,¹²⁻¹⁴ irrespective of the blood pressure and age of the patient, because susceptibility of the muscle to additional damage after the crush event may be decreased.³³ Despite interest in recording intracompartmental pressure, the surgeon should not hesitate to open a compartment that looks suspicious.^{22,29} The herniation of the muscle mass during fasciotomy will confirm the diagnosis.

The clinical part of the study was limited by its dependency on such subjective data as "massive" swelling, "excruciating" pain, tenseness, and so forth. Nevertheless, in every case the patients were examined and assessed by the same two surgeons, giving homogeneity to the grading scales referred to in Table I.

Surgical Treatment

Apart from those compartment syndromes caused by massive fluid extravasation in which nonsurgical treatment (e.g., manual pumping) may have a role,³⁰ once the diagnosis has been made, immediate surgical decompression of the affected compartments (and subcompartments³⁴) should be performed without delay.²⁶ Release of the carpal canal, as recommended by Ouellette and Kelly,¹⁸ was not universally performed; rather, it was considered only when

signs and symptoms pointed to acute carpal tunnel syndrome.³⁵⁻³⁸

In three patients the distal volar forearm was found to be tense on palpation. In two patients, measurements taken at the distal and proximal volar forearm levels yielded pathologic values distally (average, 60) and normal values³⁹ proximally (average, 18). All had concomitant acute carpal tunnel syndrome, and after opening the carpal canal, further release of the distal antebrachial fascia was performed in an attempt to decompress a hypothetical distal forearm compartment. Muscle, mainly flexor carpi ulnaris and adjacent flexor superficialis, bulged through the incision, making primary closure impossible (Fig. 3). The fascia of the pronator quadratus^{40,41} was also released, but the muscle was found to be normal. Reservations may arise as to the existence of the compartment referred to above, because there is no close space at this level. However, other "open" compartments, such as the carpal tunnel,³⁵⁻³⁸ have been described in the literature and found consistently in experiments.⁴² The syndrome may in fact be a form termed by Gardner as "sublimis syndrome."⁴³ Rather than

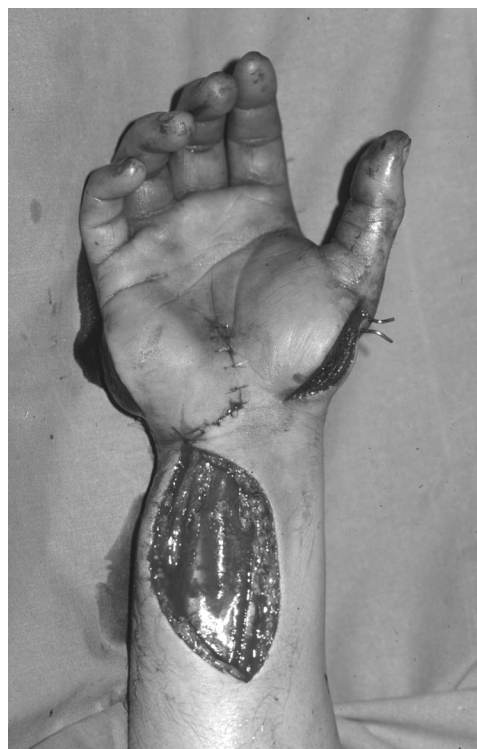

FIG. 3. In patient 5, generalized hand compartment plus acute carpal tunnel plus distal forearm compartment (sublimis compartment). Note the muscles bulging through the thenar and hypothenar incisions and the impossibility of closing the distal forearm incision.

describe a new entity, we hypothesize that by releasing the distal antebrachial fascia, the surgeon may abort the vicious cycle of increased capillary permeability-edema-ischemia and the progression to a full-blown volar forearm compartment syndrome. Recognition of the sublimis-distal forearm compartment syndrome will explain the different values recorded in the proximal forearm and distal forearm in two patients (in the other patient, no measurements were taken proximally). It will also explain why some forms of carpal tunnel syndrome that occur after "simple" Colles fracture do not respond to conventional release inasmuch as the median nerve is actually compressed "three inches above the wrist," as described by Lewis.⁴⁴

In summary, any hand crush injury accompanied by massive swelling and tenseness on palpation should alert the surgeon to the possibility of acute hand compartment syndrome, despite the absence of classic signs and symptoms. We recommend that practitioners systematically record intracompartmental pressure in any patient with a severe crush injury to all or part of the hand, and that a fasciotomy be routinely considered, inasmuch as we have found that the incidence of hand compartment syndrome is much higher than might be expected from the literature. From our investigations we further conclude that if the concomitant compartment syndrome is appropriately treated, crush injury to the hand carries a prognosis as bad as that of the associated injuries. We firmly believe that occult-unrecognized compartment syndromes are involved in the frozen hand, first web retraction, limited motion, and other sequelae attributed to the "crush hand syndrome."

Francisco del Piñal, M.D., Dr. Med.
Calderón de la Barca 16-entlo
E-39002 Santander, Spain
drpinal@ono.com

REFERENCES

1. Mason, M. L., and Bell, J. L. The crushed hand. *Clin. Orthop.* 13: 84, 1959.
2. Nemethi, C. E. Crushing injury to the hand: Prevention of ischemic contracture. *Calif. Med.* 90: 207, 1959.
3. Entin, M. A. Crushing and avulsing injuries of the hand. *Surg. Clin. North Am.* 44: 1009, 1964.
4. Carter, P. R. Crush injury of the upper limb: Early and late management. *Orthop. Clin. North Am.* 14: 719, 1983.
5. Jepson, P. N. The classic: Ischemic contracture. Experimental study. *Clin. Orthop.* 113: 3, 1975.
6. Zancolli, E. Finochietto's ischemic contracture and nonischemic intrinsic-plus deformities. In E. Zancolli (Ed.), *Structural and Dynamic Bases of Hand Surgery*, 2nd Ed. Philadelphia: Lippincott, 1979. Pp. 284-313.
7. Buck-Gramcko, D. La rétraction ischémique de la main. In R. Toubiana (Ed.), *Traité de Chirurgie de la Main*, Vol. 5. Paris: Masson, 1995. Pp. 104-116.
8. Zancolli, E. A. Ischemic contractures. In J. G. McCarthy, J. W. May, and J. W. Littler (Eds.), *Plastic Surgery: The Hand*, Vol. 8. Philadelphia: Saunders, 1990. Pp. 5033-5052.
9. Bunnell, S., Doherty, E. W., and Curtis, R. M. Ischemic contracture, local, in the hand. *Plast. Reconstr. Surg.* 3: 424, 1948.
10. Smith, R. J. Intrinsic contracture. In D. P. Green, R. N. Hotchkiss, and W. C. Pederson, (Eds.), *Green's Operative Hand Surgery*, Vol. 1, 4th Ed. New York: Churchill Livingstone 1999. Pp. 604-618.
11. Spinner, M., Aiache, A., Silver, L., and Barsky, A. J. Impending ischemic contracture of the hand: Early diagnosis and management. *Plast. Reconstr. Surg.* 50: 341, 1972.
12. Mubarak, S. J., Hargens, A. R., Owen, C. A., Garetto, L. P., and Akeson, W. H. The wick catheter technique for measurement of intramuscular pressure: A new research and clinical tool. *J. Bone Joint Surg. (Am.)* 58: 1016, 1976.
13. Gelberman, R. H., Garfin, S. R., Hergenroeder, P. T., Mubarak, S. J., and Menon, J. Compartment syndromes of the forearm: Diagnosis and treatment. *Clin. Orthop.* 161: 252, 1981.
14. Botte, M. J., and Gelberman, R. H. Acute compartment syndrome of the forearm. *Hand Clin.* 14: 391, 1998.
15. Failla, J. M. Compartment syndromes and ischemic contracture: Hand, wrist, and forearm. In W. P. Cooney, R. L. Linscheid, and J. H. Dobyns (Eds.), *The Wrist: Diagnosis and Operative Treatment*, Vol. 2. Mosby: St. Louis, 1998. Pp. 1107-1136.
16. Rowland, S. A. Fasciotomy: The treatment of compartment syndrome. In D. P. Green, R. N. Hotchkiss, and W. C. Pederson (Eds.), *Green's Operative Hand Surgery*, Vol. 1, 4th Ed. New York: Churchill Livingstone, 1999. Pp. 689-710.
17. Salisbury, R. E., McKeel, D. W., and Mason, A. D., Jr. Ischemic necrosis of the intrinsic muscles of the hand after thermal injuries. *J. Bone Joint Surg. (Am.)* 56: 1701, 1974.
18. Ouellette, E. A., and Kelly, R. Compartment syndromes of the hand. *J. Bone Joint Surg. (Am.)* 78: 1515, 1996.
19. Halpern, A. A., Greene, R., Nichols, T., and Burton, D. S. Compartment syndrome of the interosseous muscle. *Clin. Orthop.* 140: 23, 1979.
20. Halpern, A. A., and Mochizuki, R. M. Compartment syndrome of the interosseous muscles of hand: A clinical and anatomic review. *Orthop. Rev.* 9(3, March): 121, 1980.
21. Wolfert, F. G., Cochran, T. C., and Filtzer, H. Immediate interosseal decompression following crush injury to the hand. *Arch. Surg.* 106: 826, 1973.
22. McQueen, M. M., Gaston, P., and Court-Brown, C. M. Acute compartment syndrome. Who is at risk? *J. Bone Joint Surg. (Br.)* 82: 200, 2000.
23. Whitesides, T. E., Haney, T. C., Morimoto, K., and Harada, H. Tissue pressure measurements as a determinant for the need of fasciotomy. *Clin. Orthop.* 113: 43, 1975.
24. Matsen, F. A., III, and Clawson, D. K. The deep poste-

- rior compartmental syndrome of the leg. *J. Bone Joint Surg. (Am.)* 57: 34, 1975.
25. Eaton, R. G., and Green, W. T. Volkmann's ischemia: A volar compartment syndrome of the forearm. *Clin. Orthop.* 113: 58, 1975.
 26. Sheridan, G. W., and Matsen, F. A., III. Fasciotomy in the treatment of the acute compartment syndrome. *J. Bone Joint Surg. (Am.)* 58: 112, 1976.
 27. Matsen, F. A., III, Winquist, R. A., and Krugmire, R. B., Jr. Diagnosis and management of compartment syndromes. *J. Bone Joint Surg. (Am.)* 62: 286, 1980.
 28. Ortiz, J. A., Jr., and Berger, R. A. Compartment syndrome of the hand and wrist. *Hand Clin.* 14: 405, 1998.
 29. Whitesides, T. E., Jr., and Heckman, M. M. Acute compartment syndrome: Update on diagnosis and treatment. *J. Am. Acad. Orthop. Surg.* 4: 209, 1996.
 30. Ouellette, E. A. Compartment syndromes in obtunded patients. *Hand Clin.* 14: 431, 1998.
 31. Lister, G. *The Hand: Diagnosis and Indications*, 3rd Ed. Edinburgh: Churchill Livingstone, 1993. Pp. 155-281.
 32. Matsen, F. A., III, Mayo, K. A., Sheridan, G. W., and Krugmire, R. B., Jr. Monitoring of intramuscular pressure. *Surgery* 79: 702, 1976.
 33. Heppenstall, R. B., Sapega, A. A., Scott, R., et al. The compartment syndrome: An experimental and clinical study of muscular energy metabolism using phosphorus nuclear magnetic resonance spectroscopy. *Clin. Orthop.* 226: 138, 1988.
 34. DiFelice, A., Jr., Seiller, J. G., III, and Whitesides, T. E., Jr. The compartments of the hand: An anatomic study. *J. Hand Surg. (Am.)* 23: 682, 1998.
 35. Adamson, J. E., Srouji, S. J., Horton, C. E., and Mladick, R. A. The acute carpal tunnel syndrome. *Plast. Reconstr. Surg.* 47: 332, 1971.
 36. Bauman, T. D., Gelberman, R. H., Mubarak, S. J., and Garfin, S. R. The acute carpal tunnel syndrome. *Clin. Orthop.* 156: 151, 1981.
 37. Mack, G. R., McPherson, S. A., and Lutz, R. B. Acute median neuropathy after wrist trauma: The role of emergent carpal tunnel release. *Clin. Orthop.* 300: 141, 1994.
 38. Szabo, R. M. Acute carpal tunnel syndrome. *Hand Clin.* 14: 419, 1998.
 39. Seiler, J. G., III, Womack, S., De L'Aune, W. R., Whitesides, T. E., and Hutton, W. C. Intracompartmental pressure measurements in the normal forearm. *J. Orthop. Trauma* 7: 414, 1993.
 40. Sotereanos, D. G., McCarthy, D. M., Towers, J. D., Britton, C. A., and Herndon, J. H. The pronator quadratus: A distinct forearm space? *J. Hand Surg. (Am.)* 20: 496, 1995.
 41. Chan, P. S. H., Steinberg, D. R., Pepe, M. D., and Beredjiklian, P. K. The significance of the three volar spaces in forearm compartment syndrome: A clinical and cadaveric correlation. *J. Hand Surg. (Am.)* 23: 1077, 1998.
 42. Cobb, T. K., Cooney, W. P., and An, K. N. Pressure dynamics of the carpal tunnel and flexor compartment of the forearm. *J. Hand Surg. (Am.)* 20: 193, 1995.
 43. Gardner, R. C. Confirmed case and diagnosis of pseudocarpal-tunnel (sublimis) syndrome. *N. Engl. J. Med.* 282: 858, 1970.
 44. Lewis, M. H. Median nerve decompression after Colles's fracture. *J. Bone Joint Surg. (Br.)* 60: 195, 1978.